



**University  
of Manitoba**

# Ophthalmology Guidelines for Family Physicians & the Emergency Department

<b>Introduction</b>	<b>1</b>
<b>Referral Guidelines</b>	<b>2</b>
Referral Categories	3
Driving to Ophthalmology Appointments	3
<b>Patients Known to Ophthalmology</b>	<b>4</b>
<b>Contacting Ophthalmology</b>	<b>5</b>
Contacting Winnipeg Ophthalmologists	5
On Call Ophthalmologist in Brandon	8
Contact Details for Retina Specialists	8
<b>Management Guidelines</b>	<b>9</b>
Chemical Injuries	9
Visual Phenomena	11
The Chronic Red Eye	12
The Acute Red Eye	13
Ocular & Peri-Ocular Pain	17
Blurred Vision & Loss of Vision	18
Orbital & Peri-Orbital Swelling	20
Eyelid and Lacrimal Pathology	21
Diplopia	22
Pupils	23
Trauma	24
Specific Paediatric Ophthalmic Presentations	30
<b>Appendices</b>	<b>31</b>
Triage Guidelines	31
Minimal Standards of Documentation	32
Eye Patches and Eye Shields	33

Use of Eye Drops and Eye Ointments	34
Everting the Upper Eyelid	35
Analgesia for Painful Eyes	36
Slit Lamp Basics	37
Using a Tonopen	40
Using an iCare Tonometer	43
Image Gallery	43

# Introduction

This document has been compiled by the Department of Ophthalmology to assist emergency physicians and family doctors in the management of patients presenting with ophthalmic complaints.

It is not intended to be a comprehensive text on ophthalmic emergencies, but rather provide reasonable guidelines for acute management and referral.

The first sections give advice on how and when to refer patients, how to deal with patients who have previously been seen by an ophthalmologist, and contact details for the ophthalmologists who take call. The latter half details common presentations, recommendations for management in the Emergency Department and how urgently they should be referred.

A gallery of representative images has also been included for reference.

It is our intention to update this document to reflect current knowledge and make it as useful as we possibly can. As it is intended to be viewed electronically, hyperlinks have been placed throughout the text to aid navigation. Please email Dr Ian Clark at [iclark@hsc.mb.ca](mailto:iclark@hsc.mb.ca) if you have suggestions on how the guidelines might be improved.

No part of this document may be reproduced without the authors' permission.

1. Department of  
Ophthalmology  
University of Manitoba

# Referral Guidelines

The purpose of these guidelines is to provide physicians with easy access to relevant information that will aid accurate diagnosis and appropriate management. Whilst there will be some patients with ocular symptoms who will not need to be seen by ophthalmology, we understand that the diagnosis is not always clear, and we are happy to help out as needed.

Residents and staff who take call will almost always have clinics or surgery throughout the working week, so it would be greatly appreciated if calls between 11pm and 7am are avoided unless they are emergent.

All referrals require a phone call to the on-call ophthalmologist. Referrals cannot be made by fax (although a faxed consult containing your details and the patient's demographics will usually be requested).

During office hours, the calls will often be taken by an assistant in the ophthalmologist's clinic. The assistant will be able to arrange an appointment and provide details of where to send the patient and their documentation. If an assistant is taking the calls then you can always ask to speak to the ophthalmologist if you need medical advice on how to deal with your patient.

**NB *Never send an unstable patient to ophthalmology.*** Patients are often seen in private offices where there are no facilities to care for unstable patients. If the patient has problems that preclude safe transfer then be certain to discuss this with the ophthalmologist so that appropriate arrangements can be made. This may include unstable medical conditions, but it also applies to cases of trauma (e.g. patients with possible unstable cervical spine injuries).

## Referral Categories

Throughout this document reference will be made to 2 categories of eye emergency:

*Emergent* and *Routine*:

- ***Routine***: the vast majority of patients fall into this category. These referrals do not need be made in the middle of the night (between the hours of 11pm and 7am). This category does include pathology that can be very distressing for the patient (such as corneal abrasions and arc eye) but seeing such patients in the middle of the night will have no bearing on their outcome.
- ***Emergent***: these referrals justify an immediate call to the ophthalmologist regardless of the time of day. There are relatively few conditions that warrant an emergent referral.

The following conditions warrant emergent referral:

- [Acute angle closure glaucoma](#).
- Suspected [central retinal arterial occlusion](#) with onset in the preceding 4 hours.
- [Serious chemical injuries](#) (especially lime).
- Suspected [endophthalmitis](#), especially in a patient with a recent history of an intraocular surgery or intraocular injection.
- [Suspected globe rupture or penetrating eye injury](#).
- [Suspected intraocular foreign body](#).
- [Third cranial nerve paresis](#) - although such patients warrant emergent referral to neurosurgery if there is evidence of an intracranial aneurysm.

## Driving to Ophthalmology Appointments

Pupil dilation is essential for a comprehensive eye examination. Some patients may not need their pupils dilated at an initial assessment (e.g. conditions that affect the ocular surface only) but patients will definitely need to have dilating eyedrops if fundus pathology is suspected.

These eyedrops blur patients' vision and they should not drive until the drops have worn off (between 2 & 6 hours). It is helpful if you advise patients about this, particularly if there are suspicions of retinal pathology, so that they can arrange alternative transportation.

# Patients Known to Ophthalmology

If the patient is seen during office hours, and they are known to ophthalmology, then it may be more appropriate to refer them to their own ophthalmologist who will have records from their previous visits.

Please be guided by the following recommendations.

## **During office hours:**

- **Recent surgical procedures:** you should first contact the *patient's own ophthalmologist*
- **Recurrence of a condition that was treated by an ophthalmologist in the preceding 12 months:** the referral should go to their *treating ophthalmologist*
- **An emergent problem:** refer immediately to the on-call ophthalmologist
- The patient should be referred to the ophthalmologist on call for the day if:
  - the patient is presenting for the first time
  - the patient is presenting with a new complaint
  - the patient is presenting with a recurrent complaint but they have not seen their ophthalmologist for *over 12 months*

## **After hours or on the weekend:**

If you feel that there is an urgent change in a patient's condition then please refer to the guidelines below and consult with the on-call ophthalmologist as appropriate.

# Contacting Ophthalmology

You will be able to find out which ophthalmologist is taking call by contacting the **Misericordia Hospital switchboard on 204-7746581**. They will be able to connect you to the appropriate number, or you can call the appropriate office during business hours (numbers below).

Please note that patients may be seen at the ophthalmologist's office or at the Misericordia Hospital. **Please be sure to clarify where the patient should go when you talk to the ophthalmologist or their assistant.**

If patients are asked to attend the Misericordia, they should first go to patient registration on the main floor.

## Contacting Winnipeg Ophthalmologists

The table below provides the subspecialty, office address, telephone and fax numbers for the ophthalmologists in Winnipeg.

Ophthalmologist	Subspecialty	Office Address	Telephone	Fax
Alberto Aguayo	Glaucoma, Cataract	Aqua i Laser 1770 Taylor Avenue Winnipeg, MB R3N 0N8	204 560 2782	204 560 1000
Robert Beldavs	Cornea, Anterior Segment, Lid Disorder, Medical Glaucoma, Cataract	Manitoba Clinic 790 Sherbrook St Winnipeg, MB R3A 1M3	204 944 1628	204 944 1629
Lorne Bellan	Oculoplastics, Cataract	Buhler Eye Centre, 2 <sup>nd</sup> Floor, Misericordia Health Centre Winnipeg MB R3C 1A2	204 788 8563	204 786 0978
Tenley Bower	Cornea, Anterior Segment, Cataract	Winnipeg Clinic 425 St. Mary Avenue 5 <sup>th</sup> floor Winnipeg, MB R3C 3T1	204 957 3255	204 947 0450
Stephen Brodovsky	Cornea, Anterior Segment, Cataract	235-444 St. Mary Avenue Winnipeg, MB R3C 3T1	204 942 4479	204 943 8558



Ophthalmologist	Subspecialty	Office Address	Telephone	Fax
David Camoriano	Comprehensive, Cataract, Refractive	425 St. Mary Ave Winnipeg, MB R3C ON2	204 957 3239	204 947 0450
Mohit Chhabra	Comprehensive, Medical Retinal	GRMC Vision Centre Suite 20, 144 6 <sup>th</sup> Street Brandon, MB R7A 3N2	204-727 1954	204-728 5248
Daniel Chin	Cornea, Cataract	302 – 1630 Ness Ave Winnipeg, MB R3J 3X1	204 942 2507	204 957 0294
Ian Clark	Pediatrics, Strabismus	Children's Hospital CE216 - 820 Sherbrook St Winnipeg, MB R3A 1R9	204 787 8500	204 787 4965
Ravi Dookeran	Vitreo-Retinal Diseases	Waterfront Eye Institute 400-200 Waterfront Drive Winnipeg, MB R3B 3P1	204-956 0333 Ext # 2	204 946 2606
Gdih Gdih	Glaucoma, Cataract, Refractive	Aqua i Laser 1770 Taylor Ave Winnipeg, MB R3N 0N8	204 560 2782	204 560 1000
Brian Gillespie	Comprehensive, Cataract, Refractive	710 Pembina Hwy Winnipeg, MB R3M 2M6	204 943 9248	204 949 1143
Lisa Gould	Glaucoma, Cataract	Winnipeg Clinic 425 St. Mary Ave, Winnipeg, MB R3C ON2	204 957 3252	204 942 0677
Andre Jastrzebski	Medical Retina, Uveitis, Cataract	Waterfront Eye Institute 400-200 Waterfront Drive Winnipeg, MB R3B 3P1	204-956 0333 Ext # 3	204 946 2606
Raagen Kanjee	Glaucoma, Cataract	Waterfront Eye Institute 400-200 Waterfront Drive Winnipeg, MB R3B 3P1	204-956 0333 Ext # 4	204 946 2606
Sylvia Kogan	Glaucoma, Cataract, Comprehensive	GEM Clinic 221-2025 Corydon Ave, Winnipeg, MB R3P ON5	204 992 4000	204 992 4006
Matthew Lee-Wing	Oculoplastics, Cataract	302 – 1630 Ness Ave Winnipeg, MB R3J 3X1	204 946 0649	204 942 2240
Richard Leicht	Vitreo-Retinal Diseases	Winnipeg Clinic 425 St. Mary Ave, Winnipeg, MB R3C ON2	204-957 3343	204-942 0677
Josh Manusow	Vitreo-Retinal Diseases	Waterfront Eye Institute 400-200 Waterfront Drive Winnipeg, MB R3B 3P1	204-956 0333 Ext # 5	204 946 2606

## Department of Ophthalmology

Ophthalmologist	Subspecialty	Office Address	Telephone	Fax
Mathen Mathen	Vitreo-Retinal Diseases	Buhler Eye Centre, 2 <sup>nd</sup> Floor, Misericordia Health Centre Winnipeg MB R3C 1A2	204 788 8564	204 786 0978
Andrew Mis	Ocular Oncology, Comprehensive, Cataract	Manitoba Clinic 790 Sherbrook St Winnipeg, MB R3A 1M3	204 788 5729	204 784 4128
Rashmi Nigam	Comprehensive, Cataract	710 Pembina Hwy Winnipeg, MB R3M 2M6	204 956 0798	204 949 1143
Jennifer Rahman	Glaucoma, Cataract	GEM Clinic, 221-2025 Corydon Ave, Winnipeg, MB R3P ON5	204 992 4000	204 992 4006
Michael Richards	Pediatrics, Strabismus	Children's Hospital CE216 - 820 Sherbrook St Winnipeg, MB R3A 1R9	204 787 8500	204 787 4965
Santiago Ruano	Pediatrics, Strabismus	Children's Hospital CE216 - 820 Sherbrook St Winnipeg, MB R3A 1R9	204 787 8500	204 787 4965
Paul Shuckett	Pediatrics & Strabismus	Children's Hospital CE216 - 820 Sherbrook St Winnipeg, MB R3A 1R9	204-787 8500	204 787 4965
Frank Stockl	Vitreo-Retinal Diseases	Aqua i Laser 1770 Taylor Avenue Winnipeg, MB R3N 0N8	204 560 2782	204-789 9237
Will Turk	Oculoplastics, Cataract	Aqua i Laser 1770 Taylor Ave Winnipeg, MB R3N 0N8	204 560 2782	204 560 1000
John van der Zweep	Comprehensive, Cataract	Buhler Eye Centre, 2 <sup>nd</sup> Floor, Misericordia Health Centre Winnipeg MB R3C 1A2	204 789 2425	204 786 0978
James Wiens	Cornea, Refractive	ImagePlus Laser Eye Clinic 306-400 St. Mary Ave Winnipeg, MB R3C 4K5	204 943 1520	204 943 6287
Karla Zuniga	Glaucoma	GEM Clinic 221-2025 Corydon Ave Winnipeg, MB R3P ON5	204 992 4000	204 992 4006

## On Call Ophthalmologist in Brandon

There is only one ophthalmologist in Brandon and he takes call roughly 2 weeks out of each month. When he is not on call the [ophthalmologist in Winnipeg](#) should be contacted about emergencies. Call the switchboard at Brandon Regional Health Centre on 204 578 4000 to have them direct your call appropriately.

Ophthalmologist	Subspecialty	Office Address	Telephone	Fax
Mohit Chhabra	Comprehensive, Medical Retinal	GRMC Vision Centre Suite 20, 144 6 <sup>th</sup> Street Brandon, MB R7A 3N2	204 727 1954	204 728 5248

## Contact Details for Retina Specialists

The ophthalmologists who specialize in retinal disease operate a separate on call rota. They should be the first point of contact for patients who are already under their care. They can also be contacted if you feel certain that your patient has retinal pathology that justifies a referral to the on-call retina specialist.

In general, patients will usually be referred to retina after having been seen by the on call ophthalmologist. Note that [symptoms suggestive of a posterior vitreous detachment or retinal detachment](#) should be referred to the on call ophthalmologist for screening.

Ophthalmologist	Office Address	Telephone	Fax
Ravi Dookeran	Waterfront Eye Institute 400-200 Waterfront Drive Winnipeg, MB R3B 3P1	204-956-0333	204 946-2606
Richard Leicht	Winnipeg Clinic 425 St. Mary Ave, Winnipeg, MB R3C 0N2	204-957 3343	204-942 0677
Josh Manusow	Waterfront Eye Institute 400-200 Waterfront Drive Winnipeg, MB R3B 3P1	204-956-0333	204 946-2606
Frank Stockl	Aqua i Laser 1770 Taylor Avenue Winnipeg, MB R3N 0N8	204 560-2782	204-789 9237

# Management Guidelines

The following section provides advice on how certain common ophthalmic complaints may be appropriately managed. These guidelines have been compiled by the Department of Ophthalmology in Winnipeg and are therefore in line with local policy and procedures.

## Chemical Injuries

- Timing is critical. The longer the exposure, the greater the potential for damage (chemicals gradually penetrate the structures of the eye, so it will take a great deal more time and fluid to effectively wash out chemicals after a prolonged exposure).
- Alkali injuries are generally worse than acids - they penetrate the eye causing liquefactive necrosis.
- Liquids are more easily irrigated from the eye so they tend to cause less damage.
- Powders and other solids can be retained under the lids or deep in the conjunctival fornices. They are therefore harder to remove and much more likely to cause serious damage than liquids. **Lime** is a common culprit that is particularly harmful as patients will often have retained clumps, which slowly dissolve, causing devastating ocular surface pathology.
- After a chemical injury there will usually be loss of some or all of the corneal epithelium (visible with fluorescein staining) and the eye will usually look very injected. However, a more sinister sign is [when the white of the eye loses its vascularity](#). This represents ocular ischaemia and is a sign of a more serious injury.

## Recommendations

- All patients with chemical injuries should be **triaged emergently** and have their tear film pH checked as early intervention will prevent ongoing damage to the eye.
- Tear film pH should be tested with universal indicator paper *before* putting any eye drops in the eye (eye drops may not be pH neutral). This is rarely a problem as the eyes are usually tearing, so the paper can be touched to the lower lid margin to wet it.

- ▶ If universal indicator paper is not available then there is a pH test on the standard urine dipstick that can be cut off and used.
- ▶ The injury is more serious when the pH is further from the normal value of 7.5 (meaning that irrigation will need to be performed for longer)
- After checking the pH it will usually be necessary to use topical anesthetic to relieve blepharospasm so that you can examine the eye.
- If the injury involved solids or powders then every attempt should be made to remove retained particles as soon as possible. This can be done using a Ringer's lactate irrigation (or normal saline if Ringer's is not available) and/or a moist cotton-tipped applicator (with liberal use of topical anesthetic).
  - If the chemical was in powder form, the eyelids must be everted to look for retained particles. [Eversion of the upper lid](#) should always be attempted as this is the most common place to find retained particles. Eversion of the lower lid is easily achieved by pulling on the skin of the lower lid.
  - Note that the superior fornix is quite deep and particles can be hard to detect. Several "sweeps" of the upper fornix should therefore be attempted (with a moist cotton-tipped applicator) to try to clear any particles that may be lodged there. Ask patients to look down when sweeping the upper fornix, and look up when sweeping the lower fornix (which is much shallower).
- After checking for retained solids (when relevant), the eye should be irrigated *immediately & liberally* with Ringer's lactate (or normal saline if Ringer's is not available). A *Morgan lens* ([www.morganlens.com](http://www.morganlens.com)) is ideal for irrigation, otherwise the lids can be held open with a speculum or fingers. Have the patient look around whilst irrigating and be sure to direct some of the fluid into the lower and upper fornices as well.
- Irrigation should be performed even if the pH is normal - irritant chemicals can still cause damage, and these should be thoroughly washed out (although 1 bag of fluid will usually be sufficient in such cases).
- The volume of fluid required to neutralize the pH will vary according to the pH of the chemical and the length of exposure. The pH should be retested 5 or 10 minutes after stopping irrigation. This allows the tear film time to equilibrate with the pH of the eye. If

the pH remains more than 0.5 away from normal (normal is 7.5) then further irrigation is advisable. 8 to 10 liters may be needed if the pH is very acidic or alkaline on presentation.

- A cycloplegic agent may be used, such as *gt. cyclopentolate 1%* (not phenylephrine as it vasoconstricts). This relieves ciliary spasm and helps with pain, although the drop does sting when administered.
- Start an antibiotic eye ointment such as *erythromycin* (avoid *gentamicin*). [Never give topical anesthetic eye drops to patients for use at home.](#)
- Routine referral unless there is [ocular ischaemia](#) or other sinister signs.

## Visual Phenomena

This refers to “seeing things” that the patient knows are not really there.

- Flashing lights & floaters
  - Patients commonly present with white flashes of light in their temporal visual field in the affected eye. These are more obvious when it is dark. In the light they may complain of looking through a “veil” or a “cobweb” and there is often a new large floater that may be described as a spider or a ring that moves about as they look from one side to another.
  - Visual acuity should not be significantly impaired (must be documented).
  - This is a common acute presentation in ophthalmology and is usually caused by a benign posterior vitreous detachment. This event can precipitate a retinal detachment, so these patients need to be seen by ophthalmology on a routine basis to rule out retinal pathology.
  - **Note:** when they see the ophthalmologist they will need to have their pupils dilated so please advise them that **they should not drive to the appointment.**
- Migraine aura
  - No referral is needed if the patient has established migraine with visual symptoms that are typical for them.

- If there are concerns that the patient may have ocular pathology then a routine referral is appropriate. If the concern is neurological then consider referring to neurology.
- Other visual phenomena: Routine referral.

## The Chronic Red Eye

The history will usually inform the diagnosis. None of the following need emergent referral.

- Blepharitis: this is a very common chronic condition that tends to affect older patients although it can be seen at any age. The classic appearance is that of thickened, red eyelid margins (around the base of the lashes) with crusting on the lashes. There may also be small cysts along the margin of the eyelids. The eyes can be mildly injected.

Patients complain of irritable, gritty discomfort, or a burning pain in the eyes which is often worse in the morning. The eyes often water due to tear film abnormalities.

There is no cure for this, but symptoms can usually be controlled with lid hygiene. An optometrist should be able to advise patients on dealing with the problem and information is available online (e.g. [Wikipedia](#)). Referral is not necessary.

- Viral conjunctivitis: gritty discomfort, [follicles in the inferior fornix](#) and a watery discharge with crusting on lashes. Consider conjunctival swab to exclude chlamydia (inform ophthalmologist if one has been sent). Wash hands well as this is usually very contagious.

The vast majority of such infections are benign, self-limiting and therefore need no referral. An artificial tear can provide symptomatic relief. Antibiotic drops are only needed if there is a bacterial super-infection with a purulent discharge. Refer if there are corneal lesions, staining with fluorescein, or an atypical history.

- Uveitis: may have history of prior episodes. Patients typically have [ciliary injection](#), photophobia, mildly reduced acuity and an aching discomfort in and around the eye. Routine referral (do not start any treatment unless asked to do so by the ophthalmologist).

- [Exposure keratopathy](#): if the eyelids cannot close properly over the eye then it will become inflamed. This happens in conditions such as VII cranial nerve paresis and when the eye is proptosed from orbital disease (e.g. Graves disease, orbital masses). Patchy fluorescein staining will be present, usually on the inferior cornea. Provide ointment to protect the ocular surface such as *Refresh Lacri-lube*. Consider taping of the eyelids to close them at night. Routine referral.
- [Episcleritis](#): this is an indolent inflammation, usually of *one sector* of the conjunctiva - quite a characteristic appearance. The area is typically slightly elevated, slightly injected and mildly irritating (rarely painful). Vision is unaffected. A good test for this condition is to apply 1 drop of *phenylephrine* 2.5%. This will blanch the affected area making it look normal, implying that the inflammation is superficial (i.e. in the episclera and not the sclera).

It needs no treatment and will settle spontaneously over a month or two. The use of topical lubricants can help to relieve symptoms. Avoid over-the-counter drops to whiten the eyes (leads to rebound vasodilation). No referral needed unless there are concerns.

- [Retained foreign bodies or undiagnosed trauma](#). See below under [Trauma](#).
- [Contact lens problems](#). Often seen with overuse (sleeping in lenses, prolonged wear). Advise immediate cessation of contact lens use, but bring the lenses in their case to their appointment. Routine referral to ophthalmology or the patient's optometrist.
- [Chronic eye drop use with hypersensitivity](#). Some patients may have tried a variety of over-the-counter eye drops and prescribed medications from various physicians in an effort to help their symptoms. This can lead to worsening symptoms, and even a periocular dermatitis. Stop all medications and refer if symptoms fail to improve.

## The Acute Red Eye

- [Endophthalmitis](#): this is an infection of the contents of the eye. It is typically seen 2-5 days after an intraocular surgery or an intraocular injection. It is usually painful and associated with a red eye and reduced vision. The inflammation is typically so severe that white cells precipitate in the lower portion of the anterior chamber giving rise to a [hypopyon](#). This is a very significant sign.



Endophthalmitis is the most feared complication of intraocular procedures and is potentially devastating (the eye can be lost). *Please contact the treating ophthalmologist straight away.* Keep the patient ***nil by mouth*** in anticipation of possible surgery.

In cases where there is no history of recent surgery, a hypopyon may be the result of severe uveitis (often HLA-B27-associated anterior uveitis). These cases (i.e. cases with no history of a recent intraocular procedure) should be referred on a routine basis to the on call ophthalmologist.

- Acute angle closure glaucoma: at risk patients (elderly, hyperopia, Inuit) can develop obstruction of the trabecular meshwork that leads to a rapid and painful rise in intraocular pressure with halos around lights and decreased vision. May cause severe nausea and vomiting. Elderly patients may present without localizing signs (such cases have been misdiagnosed as an acute abdomen).

Signs include red eye, reduced acuity, corneal edema & a mid-dilated and unreactive pupil. The eye will feel hard to touch (through the eyelid) compared to the unaffected eye when palpated.

If you have a Tonopen or iCare tonometer available then use it to check the intraocular pressure (IOP) in *both eyes* to help verify the diagnosis. The IOP is typically 30-50mmHg (normal is usually < 20mmHg).

More damage will occur if the attack is not broken, so the aim is to get the IOP back to physiological levels (< 20mmHg) as quickly as possible.

Treatment:

- 500mg *acetazolamide* PO unless contraindicated (renal pathology) to reduce aqueous production.
- *gt. pilocarpine* 1 or 2% to constrict the pupil. Administer 1 drop and repeat after 15 minutes. It is also advisable to give the drop to the contralateral eye (for prophylaxis).
- Firm massage of the eye can break the cycle rapidly. You may consider this intervention as it can save the sight in an eye. Administer several drops of topical anesthetic to the eye and use the same drop to moisten the tip of a cotton-tipped

applicator. Apply *firm* pressure, initially to the peripheral cornea with the cotton-tipped applicator, rolling it around to indent the eyeball. This will distort the anatomy around the trabecular meshwork and can open up a space to allow aqueous to escape, dropping the IOP. You should see the tip making an indent on the surface of the eye if you are pressing firmly enough. Massage the eye in this fashion for a couple of minutes (in 5 second bursts with a 5 to 10 second pause in between) then check the IOP again. Continue to massage intermittently until the IOP is < 20mmHg, If you are not getting a response, then consider applying pressure over the mid-peripheral or central cornea (follow this [link](#) for more information). Stop after 10-15 minutes if there is no improvement.

- This warrants **emergent referral** if the pressure remains high.
- Uveitis: may have history of prior episodes. Patients typically have [ciliary injection](#), photophobia, mildly reduced acuity and an aching discomfort in and around the eye. The hallmark is the presence of cells in the anterior chamber. Routine referral. No need to start any treatment unless asked to do so by the ophthalmologist.
- [Subconjunctival hemorrhage](#): a *confluent* bleed that obscures the conjunctival blood vessels. It will be patchy and less dense at its edges. Seen with [trauma](#) but may also occur with Valsalva, vomiting, coughing...

No treatment needed unless the conjunctiva is bulging or prolapsing between the closed lids. If this is the case then an eye [ointment](#) will prevent desiccation/ulceration (e.g. *Refresh Lacri-lube* QID/PRN until settled). No referral needed if spontaneous.

- [Arc eye](#) (thermal or ultraviolet keratopathy): often seen when welding without face protection. Can be very uncomfortable so simple analgesia may be needed. Diffuse fluorescein staining of the cornea, typically seen in a horizontal band between the eyelids. Can be treated with cycloplegia (*gt. Cyclopentolate* 1% t.i.d.) for analgesia and an eye ointment q.i.d. (either an “artificial tear” or antibiotic) until symptoms settle. An [eye pad](#) may help relieve symptoms. No referral needed unless failing to settle. [Never give topical anesthetic eye drops to patients for use at home](#).
- [Bacterial keratitis](#): this presents as a painful red eye (usually a foreign body sensation). It is most commonly seen in contact lens wearers (especially when contact lens hygiene

is poor, when lenses are worn daily for extended periods, or when people sleep in their lenses). Vision is usually unaffected.

The characteristic finding is a small creamy-white spot on the surface of the cornea, usually only a millimeter or so in diameter. This “infiltrate” is a solitary colony of bacteria (like you see on an agar plate).

The contact lens must not be worn (but *do not discard it* - bring the lens in its case to the ophthalmologist in case we feel that it needs to be sent for culture). Start on topical fourth-generation fluoroquinolone (*gatifloxacin* or *moxifloxacin*), using one drop every 15 minutes for the first 2 hours then hourly until advised otherwise. [Never give topical anesthetic eye drops to patients for use at home](#). Routine referral.

- [Herpes simplex keratitis](#): this is a recurrent condition that has a very characteristic appearance with fluorescein staining. The eye will have sharp pain, it will often appear mildly injected, and the visual acuity may be normal or slightly reduced. Corneal sensation will be reduced when compared to the fellow eye.

The hallmark of this condition is a “[dendritic ulcer](#)”: a thin, linear, branching epithelial ulcer with club-shaped terminal bulbs at the end of each branch.

DONOT TREAT THIS WITH STEROIDS as this will provoke rapid progression and a corneal melt. [Never give topical anesthetic eye drops to patients for use at home](#).

Treat with *gt. trifluridine* 1% (*Viroptic*) 9 times a day or an oral anti-viral (such as *valacyclovir* 1g b.i.d. for 1 week) instead. Routine referral.

- [Herpes zoster ophthalmicus](#) (shingles): the [dermatomal vesicular rash](#) seen with V<sub>1</sub> Herpes zoster is characteristic. Start a suitable oral antiviral straight away (such as *valacyclovir* 1g t.i.d. for 1 week). Routine referral to check for signs of ocular involvement.

If the disease is bilateral, or if a patient under 40 years is affected, then it may represent the first manifestation of HIV.

- [Episcleritis](#): see above.
- [Scleritis](#): this is an *intensely* painful inflammation of the sclera (so severe that patients are often woken from sleep at night). The affected area is usually a brawny red and

acutely tender to any pressure. Vision is usually impaired. Unlike [episcleritis](#) (which is *not* usually painful), there will be *no* blanching of the blood vessels in the affected area after topical *phenylephrine* 2.5%. 50% have systemic disease (often a connective tissue disease). Routine referral.

- Acute allergic conjunctivitis: this is rarely seen by ophthalmologists as the dramatic [chemosis](#) (conjunctival edema) that is characteristic of this condition usually settles rapidly (within a few hours). The episode is provoked by the contact of an allergen with the conjunctiva; this is often pollen or spores from the garden. The eyes itch, water and the conjunctiva balloons to look like a white jelly around the cornea.

Treat with oral antihistamines, cold compresses and reassurance. No referral needed.

- Foreign bodies or other trauma. See below under [Trauma](#).

## Ocular & Peri-Ocular Pain

It is possible that patients may have little or no external signs of any ocular pathology yet complain of pain in or around the eye. The nature and location of the pain may point towards a diagnosis:

- A sharp pain in the eye usually points to a problem on the cornea (FB, abrasion...).
- Dull aching pain (similar to toothache) suggests intraocular inflammation ([uveitis](#)).
- Severe pain in and around the eye with an acute onset may be [acute angle closure glaucoma](#). The eye will be red with a hazy cornea and mid-dilated pupil. If these features are not present then consider [scleritis](#) (which is also extremely painful).
- A dull ache behind an eye which is worse on eye movements is characteristic of [optic neuritis](#).
- Itching is characteristic of allergic disease.
- Pain around the eye may be due to sinusitis - always consider this diagnosis.
- The symptoms & signs of [giant cell arteritis](#) should be considered in patients > 50 years.

Assessment should include:

- Visual function (acuity, RAPD...).
- Slit lamp assessment for signs of uveitis.

- Look for signs of a dermatomal vesicular rash that may point to [Herpes zoster ophthalmicus](#).
- Look for clinical evidence of sinusitis.
- Exclude [giant cell arteritis](#) (pain in the temples, jaw claudication, tenderness in the temporal arteries and scalp, systemic malaise - blood work may be indicated).

Make a routine referral for these complaints.

## Blurred Vision & Loss of Vision

Vision is complex and it is important to be clear about the nature of the patient's symptoms, as this will inform the differential diagnosis:

- Monocular vs. binocular
- Severity of vision loss (mild blurring vs. no perception of light)
- Timing of onset (seconds vs. months)
- Pattern of vision loss (entire visual field affected vs. a discrete patch in the central or peripheral vision)
- Presence of any associated symptoms, past ocular/medical history, or family history

*NB Always check blood pressure as malignant hypertension is a cause of blurred vision; this medical emergency can occur in any age group.*

### Unilateral Loss of Vision

There are many conditions that need to be considered in the differential. The immediate issue is identifying the urgent cases:

- [Central retinal artery occlusion](#): rapid (in minutes), painless loss of vision in an older arteriopath (>50yrs). Fundoscopy shows markedly attenuated vessels, retinal pallor and a "cherry red spot" at the fovea. You may see the column of blood in the retinal veins broken into segments due to the poor/absent arterial flow.

This condition has a very poor prognosis and the chances of any intervention having an impact on the visual outcome are slim. Nonetheless, if the onset was less than 4 hours ago then make an **emergent referral** as the on call ophthalmologist may wish to try to dislodge the embolus by dropping the intraocular pressure rapidly.

- Amaurosis fugax: this is transient, painless, monocular loss of vision caused by embolic occlusion of a retinal artery. The onset is over minutes (just the same as a central retinal artery occlusion) and complete recovery occurs spontaneously, usually within hours. Routine referral.
- Giant cell arteritis (GCA): this is a potentially lethal systemic vasculitis that often presents with visual symptoms (acute unilateral visual loss from ischemic optic neuropathy, diplopia from cranial nerve paresis or transient visual loss).

This condition can evolve rapidly with vision loss in hours. Maintain a high index of suspicion and treat immediately if the diagnosis is suspected.

- Patients over 50 years.
  - History of polymyalgia rheumatica is a strong risk factor.
  - Other symptoms may include temporal headache, jaw or tongue claudication (pain comes on after exertion, in contrast to TMJ pain), scalp tenderness or even ulceration, lethargy, loss of appetite, weight loss.
  - All patients need ESR, CRP and CBC (as thrombocytosis is associated with GCA), which should be sent urgently.
  - If index of suspicion is high then patient should be ***started immediately on oral prednisone 1mg/kg/day*** ( $\pm$  H<sub>2</sub> antagonist or proton pump inhibitor).
  - Routine referral to ophthalmology if there are visual symptoms
  - Refer to rheumatology if there are no visual symptoms but you think that the patient may have GCA).
- Central retinal vein occlusion: painless, rapid loss of vision. Typically have a history of cardiovascular risk factors and age > 50 years. Fundoscopy shows widespread bright red retinal hemorrhages. Routine referral.
  - Acute angle closure glaucoma should be considered as it can be painless in rare cases.
  - Retinal detachment: gradually increasing loss of peripheral vision, painless, usually associated with flashing lights and new floaters. Myopes, patients who have had cataract surgery, and those with a family history of retinal detachment are at particular risk. Routine referral.

- Diabetic complications: including vitreous hemorrhage & diabetic maculopathy. Routine referral. Consider blood work, blood pressure, urinalysis and alerting the family doctor of poor control or other complications.
- Optic neuritis: typically unilateral visual loss in a young adult coming on over several days. Usually associated with retrobulbar aching pain on moving the affected eye. Acuity may be relatively normal but colour vision will usually be affected (red desaturation), they may have a central scotoma and you would expect to see a relative afferent pupillary defect. Routine referral.
- Macular degeneration: this affects the central vision of elderly patients. It usually has an insidious onset but acute changes (subretinal bleeding) may cause the patient to present as an emergency. This will usually cause a painless decrease in central vision. Blood may be seen at the macula. Routine referral.
- Other causes include refractive error (test pinhole visual acuity), cataract, posterior capsule opacification in patients with a history of cataract surgery, and other retinal diseases. Routine referral.

## Orbital & Peri-Orbital Swelling

The commonest cause of orbital and peri-orbital swelling is cellulitis. An important distinction exists between infections arising in the orbit, and infections that arise in the skin (so called “pre-septal” cellulitis: a fibrous septum divides the orbit from the tissues that are anterior to it).

Pre-septal cellulitis is no different from cellulitis elsewhere in the body. This usually occurs following local trauma (insect bites, plucking eyebrows). Infections within the orbit are far more serious as they pose a risk of vision loss (through increased intra-orbital pressure) and of posterior spread (which can lead to meningitis and brain abscess formation). Orbital infections usually occur secondary to sinusitis with direct spread of infection into the orbit.

Despite the differing severity, the two conditions can be very hard to discern clinically as both present with marked lid swelling (often unable to open the eye), redness, warmth of the affected tissues and tenderness. The key to differentiating the two is to look for the following signs of orbital disease (which would suggest orbital cellulitis):

- Reduced visual acuity
- A relative afferent pupillary defect
- Red desaturation (a red target appears darker or less saturated with the affected eye)
- Proptosis
- Limited eye movements giving rise to binocular diplopia

### Management

- Blood should be sent for CBC and culture prior to the administration of any antibiotics.
- A CT scan of the orbits can detect the presence of sinus disease & identify whether or not an intraorbital abscess is present.
- If cellulitis is suspected then IV antibiotics should be administered after sending blood cultures. *Ceftriaxone* is a reasonable empiric choice based on the likely sinus pathogens.
- An ENT consult is needed if the orbital CT shows the presence of an associated sinusitis.
  - Look for a sub-periosteal abscess (or the much rarer orbital abscess) on the CT.
- Confirmation of orbital cellulitis justifies an ID consult due to the serious complications that can potentially arise.
- Routine referral.

Other causes of orbital swelling exist such as thyroid orbitopathy (Graves disease), carotid-cavernous fistulae and orbital tumors. These would also warrant routine referral.

## **Eyelid and Lacrimal Pathology**

All the following conditions warrant routine referral

- [Chalazion](#): these benign lesions form close to the lid margin and are more common in children and young adults. They form when secretions from a meibomian gland are retained. Early on they are discrete, firm nodules that may grow as large as a pea.

If the secretions seep out of the gland into the surrounding skin a foreign body reaction develops. This can resemble a localized cellulitis (see image gallery for the varied presentations).



If the lesion appears typical and it is not bothering the patient then reassurance that it will resolve spontaneously may be all that is needed. If there are concerns then make a routine referral.

- [Pre-septal cellulitis](#). See above.
- [Dacryocystitis](#): this is an infection of the lacrimal sac on the lateral aspect of the nose. It will cause a variable degree of surrounding cellulitis depending on its severity. The lacrimal sac will be swollen with pus, and it may be possible to see pus coming out of the lacrimal punctae when pressure is applied to the sac.

Draw blood for CBC and cultures prior to starting any antibiotic. Start empiric treatment with IV *cephalosporin* or *amoxicillin-clavulanate* and make a routine referral, as drainage may be beneficial.

- [Lacrimal trauma](#): see below.

## Diplopia

- **Monocular**: usually due to cataract. Routine referral.
- **Binocular**: due to misalignment of the visual axes of the two eyes. (Always consider the possibility of [giant cell arteritis](#)).
  - ▶ [Third cranial nerve paresis](#) - this is a potential **medicalemergency**.  
The signs may include ptosis, pupil dilation and poor/absent adduction, elevation and depression of the affected eye (leaving the eye exotropic).
    - If the patient is over 40 with identifiable cardiovascular risk factors, a complete third nerve palsy, and no other signs or symptoms, then a microvascular etiology is likely. Such patients should be discussed with the on call ophthalmologist for routine review.
    - All other patients (“partial” third nerve paresis, patients without cardiovascular risk factors, young patients, and patients with signs or symptoms that may suggest an intracranial bleed) need an **emergent CT angiogram or MR angiography** to exclude an intracranial aneurysm (usually of the posterior communicating artery). If

an aneurysm is found, then refer emergently to neurosurgery. Patients with no intracranial pathology need a routine referral to ophthalmology.

- Occasionally, [giant cell arteritis](#) may present as a third nerve paresis (or other cranial nerve paresis), so blood should be sent for ESR, CRP & CBC.
- ▶ Traumatic - often associated with an [orbital fracture](#).  
In this setting diplopia is commonest in upgaze and downgaze. A CT should be requested asking for coronal views through the orbits. Routine referral to ophthalmology, but refer to plastics/maxillofacial surgery if a fracture is seen on the scan.
- ▶ Other  
This group includes patients with sixth cranial nerve paresis, thyroid orbitopathy, decompensated phorias, etc. ... Routine referral.

## Pupils

The commonest pupil abnormality presenting as an emergency is unexpected [pharmacologic dilation](#) of one or both pupils. This will probably be associated with blurring of the vision (especially for reading) due to impaired accommodation. The anisocoria (difference in pupil size between the two eyes) is typically very dramatic in such cases.

There are many agents that have a sympathomimetic or parasympatholytic effect on the pupil - some are obvious (e.g. eye drops like *atropine* and *cyclopentolate*) but other causes can be much harder to identify:

- Ipratropium bromide inhalers
- Scopolamine patches
- Plants such as Angel's Trumpet, etc...

Ensure that there is no neurological impairment (in particular, you must ensure that there are no signs of a [third cranial nerve paresis](#)). If the cause is clear then no referral is needed. Routine referral if there is no obvious explanation.

There are many other causes of pupil abnormalities, but these abnormalities will usually be seen in association with other problems (e.g. [traumatic mydriasis](#) after blunt trauma to the eye, or an RAPD secondary to a central retinal artery occlusion).

## Trauma

**NB It is essential that patients are stable if they are being referred directly to ophthalmology. Patients with trauma to the eyes may have associated head/neck injuries that can easily go unnoticed in the setting of an obvious, severe eye injury.**

**Always consider the possibility of injuries to the cervical spine, or intracranial injuries, image as needed, and refer to Gold Trauma Service at Health Sciences Centre if there are any concerns.**

**Eye injuries (even a ruptured globe) should never delay the treatment/evaluation of more serious injuries to life & limb.**

(Click the appropriate link to return to sections on [blunt trauma](#), [blow-out fractures](#), [eyelid trauma](#), [globe rupture](#), or [head trauma](#).

### Corneal abrasion

The history is usually clear in these cases. Ensure that there is no evidence of a retained foreign body (evert the lower & [upper eyelids](#) in all cases) and treat with an antibiotic ointment q.i.d. until symptoms resolve.

When the symptoms have settled it is advisable for the patient to continue to use an eye ointment every night just before going to sleep to prevent a recurrent corneal abrasion.

These recurrent abrasions occur as the eye becomes dry when sleeping, which can lead to the inside of the eyelid becoming stuck to the healed epithelium. When the patient wakes and opens the eye, the epithelium is pulled off the cornea, causing a recurrence of intense pain and tearing. This history is very characteristic. Advise use of an artificial tear ointment (e.g. *Refresh Lacri-lube*) for a month or more to minimize this risk.

Eye patches are not necessary, but may be used if the patient finds it helpful. If using an eye patch it is best to use 2 (one on top of the other) as the aim is to prevent opening of the eyelid when the pad is on. [Never give topical anesthetic eye drops to patients for use at home](#).

No referral is needed if the symptoms settle.

## Superficial foreign body

The history is usually diagnostic. Foreign bodies on the conjunctiva, or in the fornix, can usually be wiped away with a cotton-tipped applicator. A [foreign body on the cornea](#) is usually more adherent and usually requires the use of an instrument such as a “golf spud” (designed for this purpose) or a 21G needle. This is best done on the slit lamp.

Always ensure that there is not another foreign body in the other eye, or hidden under an eyelid. The [upper lid should always be everted](#) to check for this.

It is important to be suspicious about the possibility of an intraocular foreign body in these cases. The history should guide you:

- Something “blowing into the eye” (when walking outdoors) will not penetrate the eye.
- Sparks from angle-grinders will not penetrate the eye.
- In cases where the injury occurred when “metal hit metal” (e.g. hammer on chisel) there is a serious risk of penetrating injuries from high velocity fragments that carry sufficient momentum to pass readily into the orbit or the eye. The CMPA mandates that these cases **MUST HAVE [PLAIN X-RAYS OF THE ORBITS](#)** to look for an intraocular or intraorbital foreign body. See below for details about investigating & managing a [suspected intraocular foreign body](#).

No referral is needed if a superficial foreign body is successfully removed and there are no other concerns. Prescribe an antibiotic eye ointment q.i.d. for 5 days. [Never give topical anesthetic eye drops to patients for use at home](#).

## Suspected intraocular foreign body

If the mechanism of injury suggests the possibility of an intraocular foreign body (IOFB) then **YOU MUST DO [PLAIN X-RAYS OF THE ORBITS](#)** to investigate the possibility. It is medically indefensible to miss the diagnosis of an IOFB without imaging.

Plain films should include a PA & 2 laterals; the laterals should be taken in up and downgaze to look for signs of a foreign body inside the eye (an IOFB will move in the 2 lateral views, whereas intraorbital foreign bodies will not).

A CT with fine slices through the orbits is the best investigation for localizing a foreign body, and should be requested if either the x-ray is suspicious, or if the history/examination is highly suggestive of an IOFB.

IOFBs are a form of penetrating eye injury and are therefore potentially devastating. They warrant an **emergent referral**. Do not administer any topical medication, keep the patient **nil by mouth** and place a [shield](#) over the eye (to ensure that there is no pressure on the globe).

NB *Ensure that the patient is covered for tetanus whilst in your department.*

### Sub-tarsal foreign body

Foreign bodies that do not embed into the eye will usually end up beneath the upper eyelid. This causes pain on blinking and gives rise to a very [characteristic pattern of fluorescein staining](#). If you see this, you must [evert the upper lid](#). The foreign body will most likely be close to the margin of the eyelid (near the base of the lashes) and can usually be wiped away with a cotton-tipped applicator. Give an antibiotic ointment q.i.d. for 5 days. [Never give topical anesthetic eye drops to patients for use at home](#). No referral needed.

### Blunt trauma and hyphema

NB See the advice about associated injuries at the [top of this section](#).

The history is usually characteristic. Patients may complain of some discomfort and reduced vision (if there is blood in the anterior chamber). In such cases, the pupil often reacts poorly and remains semi-dilated (known as [traumatic mydriasis](#)).

If there has been sufficient bleeding, a [hyphema](#) will develop: the blood will settle in the lower portion of the anterior chamber.

Depending on the mechanism and force of the injury, more extensive damage may have occurred to the eye and orbit. Consider the possibility of a [globe rupture](#) or [blow-out fracture](#).

These patients should have their intraocular pressure measured, if possible, as a high pressure (> 30mmHg) is a cause for concern (this can be particularly problematic in patients with sickle cell disease).

The patient must be advised to rest. Strenuous activity can dislodge any clot and cause a secondary bleed; this is typically much worse than the initial bleed. Re-bleeds can occur even after coughing, or a Valsalva manoeuvre, so counsel the patient accordingly.

It is also helpful to keep the head upright most of the time (i.e. sleep with extra pillows), as this will keep the blood that has settled where it is (rather than re-mixing with the aqueous, thereby compromising the vision).

If the diagnosis is clearcut, prescribe a topical steroid q.i.d. (*dexamethasone* 0.1% or *prednisolone acetate* 1%). Routine referral.

### **Blow-out fractures of the orbit**

NB See the advice about associated injuries at the [top of this section](#).

When there is a significant blunt injury to the orbital area, weak points in the orbital walls can fracture. The commonest “wall” to fracture is the orbital floor, followed by the medial wall. The mechanism of injury is typically with a larger object, such as a fist, soccer ball or a steering wheel. The energy is transferred directly to the orbital bones and fractures are more common. Smaller objects (such as a golf ball) tend to dissipate most their energy by damaging the globe and are less likely to cause a blow-out.

The hallmark of a blow-out fracture is [reduced ocular motility](#) and diplopia. This occurs due to entrapment of orbital tissues in the fracture. If the floor has fractured, the diplopia is likely to be worst in upgaze, with increasing vertical separation of the images (injury to the infraorbital nerve will also lead to numbness of the lower lid on the affected side). If the medial wall is fractured, abduction is likely to be limited, with increasing horizontal separation of the images as the patient attempts to abduct the eye.

Injury to the globe can occur in these patients. Look for a [hyphema](#), reduced vision, and check for an RAPD (as optic nerve avulsion can rarely occur).

The best investigation to look for a blow-out fracture is a CT of the orbits *with coronal views*. Look for [prolapsed orbital tissue](#), and fluid levels in the sinuses.

If a blow-out fracture is confirmed, then a referral to plastics or maxillofacial surgery is needed (depending on which service is covering facial trauma for your department). Avoid nose-blowing, which leads to surgical emphysema and can seed infection into the orbit. Routine referral to ophthalmology.

## **Eyelid trauma**

NB *Always consider the need for tetanus immunization if there is an open wound*, and see the advice about associated injuries at the [top of this section](#).

Any sharp injury near the eye may have also involved the globe, or even the brain.

[Apparently innocent lid lacerations](#) may be the only sign of a penetrating eye injury, or injury to the frontal lobe. The mechanism of injury must be considered. Refer if there are any concerns.

Small wounds that are uncomplicated, that do not involve the lid margin, and that are well-away from the [lacrimal system](#) may be treated in the Emergency Department.

If the lid margin is involved, or if there is a suspicion about other injuries, then a routine referral is warranted. There is no need to make any attempt to suture lid margin lacerations as they need careful closure to prevent sight-threatening complications.

## **Trauma to the lacrimal system**

The upper and lower lacrimal punctae are situated near the medial canthus. They drain tears into the upper and lower lacrimal canaliculae. These course medially, parallel to the lid margin, join together, then continue to the lacrimal sac on the lateral aspect of the nose.

[Lid lacerations near the medial canthus](#) are therefore likely to involve the lacrimal system.

Care must be taken when repairing these lacerations to ensure that every effort is made to preserve the patency of the system. If there is a laceration near the medial canthus then it should be referred to the on call ophthalmologist, even if the lid margin is in tact.

As with other penetrating injuries near the eye, be suspicious about the possibility of globe and/or brain injuries.

## **Suspected globe rupture, or penetrating eye injury**

NB See the advice about associated injuries at the [top of this section](#).

The globe can be ruptured by blunt forces (where the eye literally bursts open), or it can be cut open by a sharp object. The former are generally far more devastating, but both are very serious injuries that can potentially lead to loss of the eye.

Some patients will show [clear evidence of a penetrating eye injury](#), with signs such as a distorted pupil (caused by iris prolapsing through a wound), blood in the anterior chamber,

herniation of intraocular contents, etc..... Others may show little sign of injury, and it is even possible to maintain 20/20 vision. It is important to recognize that these injuries are often painless, so the absence of pain is not an indicator of a trivial injury.

The key is to bear in mind the mechanism of injury, and to maintain a high index of suspicion.

If there is evidence of an open globe, or if you suspect that there may be an open globe, do not apply any eye drops or ointment, and cover the eye with a [shield](#). This shield should ensure that nothing places any pressure on the globe (follow the link above for an explanation).

Prior to referral to ophthalmology, make sure that the patient is stable, and that there are no other injuries that need more urgent attention.

Suspected globe rupture or penetrating eye injury warrants an **emergent referral**. Keep the patient ***nil by mouth*** in anticipation of surgery.

*NB Ensure that the patient is covered for tetanus whilst in your department.*

### Severe head trauma

NB See the advice about associated injuries at the [top of this section](#).

If a patient has severe head injuries that involve the eyelids, eyes and/or orbits, then please try to examine the eyes early in the secondary survey. The reason for this is that the trauma will lead to increased swelling of the lids; before long it will be impossible to open them to examine the eyes.

- Document pupil reactions, specifically whether or not there is an RAPD (may indicate optic nerve trauma).
- Check for obvious signs of globe rupture or penetrating injuries.
- Look for a hyphema.

In cases of severe head injury, any problems with the eyes come secondary to the other injuries. Nonetheless, if the patient is going to the OR, the on call ophthalmologist may wish to take that opportunity to examine the eyes. Notify them about the patient, your findings, and what the immediate management will be so that they can make plans to assess the patient.



## Specific Paediatric Ophthalmic Presentations

Most children with an acute eye problem will fall into one of the categories listed above. Follow the guidelines, and refer as appropriate to the [on call ophthalmologist](#) or the [patient's own ophthalmologist](#) (if they have one).

However, two conditions deserve specific mention.

### Ophthalmia neonatorum

This is a [purulent, mucopurulent, or mucoid discharge from one or both eyes](#) in the first month of life with diffuse conjunctival injection. It can be harmless, but some cases are caused by organisms that may be associated with significant systemic disease in both the infant and the mother.

All cases should be discussed with a paediatric ophthalmologist during office hours (telephone 204 787 8500), or the on call ophthalmologist at other times.

### Suspected child abuse

If a young child presents with injuries that are inconsistent with the history, or with signs of trauma that give rise to concerns of abuse, then the patient must be discussed with the on call paediatrician.

If there are also eye injuries that need attention, then discuss these with the on call ophthalmologist.

# Appendices

## Triage Guidelines

- If there is a history of a possible chemical injury, then the patient must be seen in triage *as an emergency* in order to have the pH of their tear film checked and documented. See the section on [chemical injuries](#) for more information.
- Document the tetanus status of all patients with open wounds (including penetrating eye injuries), and immunize when appropriate.

## Minimal Standards of Documentation

### Visual Acuity

It is imperative that every patient presenting with an ophthalmic complaint have their visual acuity properly documented:

- Use distance glasses, or contact lenses when appropriate (not “reading glasses”, which correct for near vision).
- standard notation is to write the test distance as the numerator, and the letter size as the denominator
  - ▶ 20/40 means that the patient was 20’ from the chart, reading letters that should be visible to normal people at 40’ (i.e. the letter line with 40 next to it)
- If the eye chart cannot be seen at 20’ then move the patient closer to the chart; document the test distance accordingly
  - ▶ e.g. 10/40 means that the patient is 10’ from the chart, reading the “40” line
- Acuties must be **uniocular** i.e. test each eye *individually*.
- If the acuity is less than expected then you can use a pinhole to see if their acuity improves (compensates for low to moderate refractive errors).

- ▶ you can make a pinhole with a piece of paper and the end of your pen; make a small hole in the paper that should be about 1mm in diameter
- If the chart cannot be read at all, then test for
  - Counting fingers (CF)
  - Hand motions (HM)
  - Perception of light (PL)
  - If the patient cannot see even a bright light shone directly in the eye, then document the acuity as “no perception of light” (NPL).

### pH Testing for Chemical Injuries

All chemical injuries should have the pH of the tear film measured using universal indicator paper on presentation to give a guide to the nature and severity of the injury.

There is a pH test on the standard urine dipstick that can be cut off and used if universal indicator paper is not available.

## Visual Requirements for Driving

There are legal considerations as well as practical considerations that must be taken into account when advising patients as to their ability to drive a vehicle. Please note that visual standards differ for commercial vehicles, and these guidelines only cover passenger vehicles.

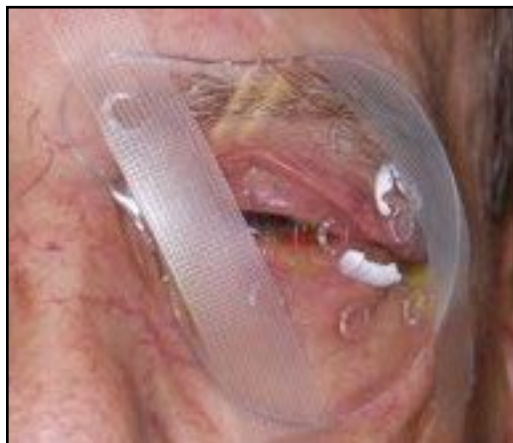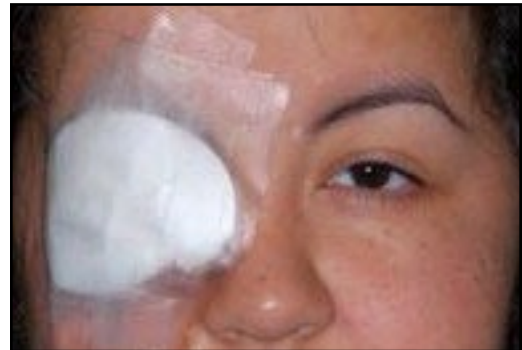Assuming that the patient had adequate vision to hold a license prior to the onset of their ophthalmic complaint:

- No patient should drive if they feel unsafe to do so, whatever their examination findings.
- A change in a patient's visual function often leads to a degree of uncertainty, and it is generally better to avoid driving until they recover, or become accustomed to the change.
- If dilating eyedrops have been used to examine the fundi, then the patient should refrain from driving until the drops have worn off (anything from 2 to 6 hours).
- An **absolute requirement** is that the patient is able to demonstrate an acuity of at least **20/50** with both eyes open.

- No diplopia - diplopia is a contraindication to driving.
  - If they have binocular diplopia, they may cover one eye to relieve their symptoms, but it is preferable to avoid driving altogether (especially after an acute change).
- No gross visual field defect when both eyes are open.
  - Loss of vision in one eye *per se* is not a contraindication to driving, but a homonymous hemianopia is an absolute contraindication.
- Some medications (notably eye ointments) will tend to blur vision and these should be avoided just before driving.

## Eye Patches and Eye Shields

An eye patch, or pad (right), is generally a soft gauze pad that has been cut into an oval shape. Patches are used to keep an eye closed (e.g. after a corneal abrasion).



An eye shield (left) is a protective cover made of solid plastic. It is designed to be taped over an injured eye. It rests on the bony orbital rim so that no pressure can be applied to the globe, and the patient cannot rub the injured eye.

### When to use a patch

Patches are used by some ophthalmologists to keep an eye closed after a significant corneal abrasion, radiation keratopathy, or chemical injury. The rationale is to prevent the healing corneal epithelium from being traumatized by blinking, to prevent pain from photophobia, and to aid healing by the close proximity of the rich vascular plexus of the conjunctiva under the eyelids.

To achieve this effectively it is usually necessary to use more than 1 patch. First, a liberal amount of antibiotic eye ointment (such as *Erythromycin*) should be placed in the eye. The eyelid should then be closed by the patient and one or two patches should be folded in half and placed over the closed eye (depending on how deep-set the eye is). Another unfolded patch should be placed over the top, and taped firmly in place. By placing several patches in this fashion there should be enough pressure on the eyelid to prevent it from opening at all. It should not be uncomfortable for the patient.

Patches are not to be used when infection is suspected, and are rarely needed for small corneal abrasions (such as after removing a foreign body).

**Note:** eye patches must ***never be used*** in this manner if there is ***any suspicion of a penetrating eye injury*** - it may provoke extrusion of intraocular contents by pressing on the open globe.

### When to use a shield

Shields are used whenever there is a suspected penetrating injury. This may be the result of trauma, or for patients recovering from intraocular surgery.

An eye patch ***should not*** be placed under the shield.

Few Emergency Departments have eye shields, but a makeshift eye shield can be made by cutting the bottom 1cm off a styrofoam coffee cup and taping this over the damaged eye.

## Use of Eye Drops and Eye Ointments

### Eye drops

Being liquid, these will drain through the lacrimal system more quickly than ointments, so they generally need to be used more frequently (sometimes every hour or more).

They do not blur the vision (unless they are mydriatics like *cyclopentolate*), so they are generally better for drivers.

They are often easier to get into the eye than an ointment. Patients who dislike eye drops can lie back so their face is pointing straight up to the ceiling and a drop or two can be placed at the medial canthus to form a small puddle. The patient can then open their eye

(or their eyelids can be parted by the person administering drops) and the medication will fall back into the tear film.

### Eye ointment

Ointments are greasy, so they tend to stick to the surface of the eye and work for longer, requiring less frequent dosing (usually no more than 3 or 4 times a day). They will blur the vision due to their oily nature.

Ointments are harder to administer due to their greasy nature. One trick is to ensure that the ointment is not cold; if the ointment is body temperature it will be less stiff. Keep the tube in a pocket close to the body and be easier to administer.

To administer an ointment it is best to pull the lower lid downwards, and squeeze a line of ointment in the lower fornix (between the lid and the globe). Then close the eye gently and keep it closed for about a minute to allow the ointment to warm up and spread over the globe, before gently wiping away any excess.

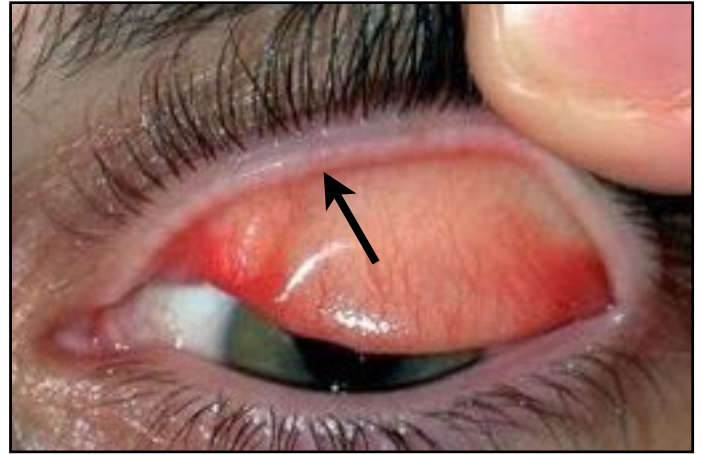## Everting the Upper Eyelid

If there is any suspicion of a retained, or sub-tarsal foreign body, then you should evert the upper eyelid. It is the commonest place for a loose foreign body to be found.

This is not a painful procedure and is easily achieved, even in children, as long as you explain what you are going to do.

1. Relieve blepharospasm with topical anesthetic drops (e.g. *Alcaine*).
2. Ask the patient to *look down* with both eyes open, and not to squeeze their eyes shut.
3. Place a cotton-tipped applicator over the upper lid crease (the line that is usually present on the skin of the upper lid about 6mm above the lid margin).
4. Grasp the lashes of the upper lid with your finger tips and rotate them upward, whilst gently pushing the cotton-tipped applicator downwards. The margin of the upper lid will rotate over the cotton-tipped applicator so that you can see the underside of the upper eyelid.

5. Look for foreign bodies in the groove that lies ~1mm behind the margin of the eyelid (as indicated by the arrow on the image). Foreign bodies can usually be wiped away with a cotton-tipped applicator.



## Analgesia for Painful Eyes

### Topical Anesthetics

The obvious solution to relieve the intense pain caused by problems on the ocular surface (abrasions, foreign bodies...) is a topical anesthetic: *proparacaine* (*Alcaine*) or *tetracaine*. These are invaluable in managing ophthalmic emergencies. They provide more or less instant relief from this type of pain, so patients are able to comfortably open their eye to allow examination.

**These drops must not be given to patients to take home** for analgesia under any circumstances. Patients will use them as soon as the pain returns, which will be every 15 minutes or more. The frequent use of these drops soon generates a toxic reaction on the ocular surface that can be more problematic than the original pathology. Cases of spontaneous perforation of the cornea have been reported due to unregulated patient administration of topical anesthetics.

### Topical Non-Steroidal Anti-Inflammatories

Drugs such as *diclofenac* (*Voltaren*) have been studied as analgesics with good reports in the literature. However, it is also well documented that they delay healing and can be associated with corneal melts. Their use should generally be avoided in the ED.

### Simple analgesics

Whilst these are not perfect for ocular pain, they are the best choice in the outpatient setting. A combination of acetaminophen and ibuprofen (when there are no contraindications) can be quite effective. Avoid opiates.



## Slit Lamp Basics

The slit lamp is basically a binocular microscope linked with a light source. These 2 parts of the slit lamp can move independently to allow you to shine the light from one direction whilst looking through the microscope from another.

A slit lamp should enhance your view of the eye. It is often the case that patients and relatives have “had a go” on the ED slit lamp and messed it up, making it hard for the unsuspecting ED physician to see clearly. Here are some pointers to help remedy the simple problems.

### The Eyepieces

These are removable and adjustable (for those with refractive errors who prefer to take their glasses off to use the microscope). Before use it is worth checking the following:

1. That both eyepieces are correctly seated - they should be pushed into the microscope as far as they can go. See figure 1 which shows the left eyepiece in the correct position and the right eyepiece (on this slit lamp it is silver) pulled out.
2. That both eyepieces are set to zero. The numbers on the eyepieces allow users who remove their glasses to correct their refractive error but in practice it is usually best for the user to wear their glasses and to keep the eyepieces set to zero. Figure 2 shows the left eyepiece set to -2.5 and the right set to zero. The left should be turned anti-



Figure 1



Figure 2



clockwise so that both are set to zero (as they are in figure 1).

3. The eyepieces can be grasped and moved together or separated so that you are able to look through both at the same time. This allows binocular viewing, giving the examiner a much better view.

### Positioning the Patient

The slit lamp table (and the patient's chair) are usually adjustable for height so that you can make them comfortable. It is helpful to know that the patient's eyes should be level with the black line on the slit lamp (indicated with the blue arrow in figure 3). This can be adjusted by moving the chin rest up and down. The chin rest is adjusted by twisting the mechanism indicated with the red arrow in figure 3.




Figure 3

The black line on the slit lamp marks the centre-point of the microscope's vertical travel. If the patient's eyes are much lower than the line you will not be able to drop the microscope low enough to examine the eyes properly.

### Slit Lamp Controls

These will vary according to the model, but the basics are usually very similar. The magnification of your view can be adjusted between low and high power. It is usually easiest to work with low power unless looking for specifics (like cells in the



Figure 4



anterior chamber). On many microscopes the magnification is adjusted by flipping a lever behind the eyepieces (as indicated with a red arrow in figure 4) or by a dial in front of the eyepieces.

Near the top of the swinging arm that houses the lamp are 2 controls that adjust the illumination. One (marked with a red arrow in figure 5) will adjust the intensity and colour of the light beam. Generally it is best to work with the brightest white light that you can.

The other control adjusts the height and orientation of the slit beam. This control is indicated with a blue arrow in figure 5. The height adjusts by twisting the knob (clockwise & anti-clockwise) whilst the

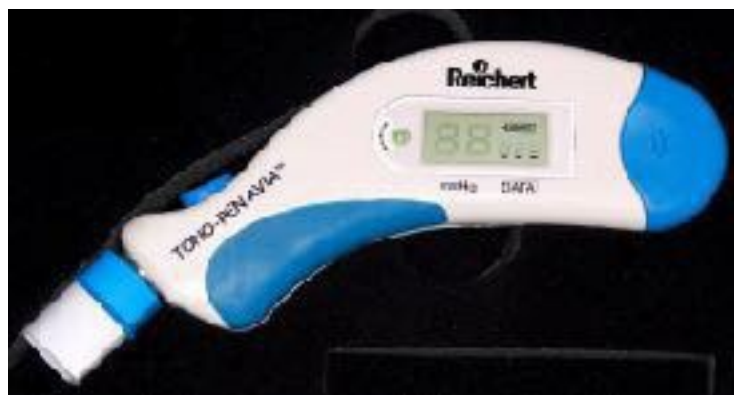orientation is adjusted by swinging the whole assembly to the right or left. It is best to keep the slit beam orientated vertically to get the most information for general purposes.

Lower down on the slit lamp assembly is a knob that controls how thick the slit beam is. This is marked with a yellow arrow in figure number 3 (above).

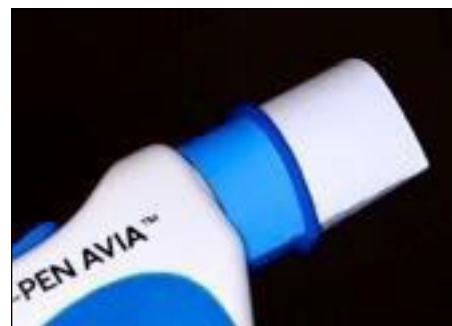Fine adjustments of the microscope position allow you to focus precisely on what you want to look at. This is achieved by using the joystick at the base of the microscope. Side-to-side movements are self-explanatory but forward and backward movements effectively allow you to focus on structures deeper in the eye, and structures that are more superficial respectively. To move the microscope up and down you twist the joystick clockwise or anti-clockwise (like a screw cap).

## Using a Tonopen

This digital tool for measuring intraocular pressure is available in 2 models: the Tonopen XL and the Tonopen Avia (shown on the right). The XL is the older model and requires calibration before use so you will usually see “CAL” on the screen when you turn it on. This indicates that it needs to be calibrated. (The Avia rarely needs calibration).



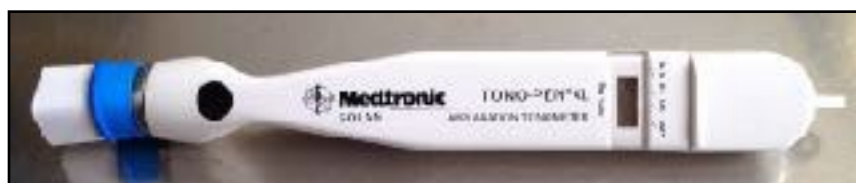Note that Tonopens should **ALWAYS** have a clean “Ocu-Film” cover over their tip to protect them from damage and dust. These covers look like small blue or white rubber condoms, and need replacing after each use. It is customary to leave the cardboard ring over the Ocu-Film (as shown in the image to the right) after a new one is placed on the Tonopen. This makes it clear to the next user that the Ocu-Film is clean, as the cardboard ring needs to be removed prior to use.




The Ocu-Film covers contain latex so the Tonopen should not be used if the patient has a latex allergy.

### Calibrating the Tonopen XL

1. The Tonopen XL is shown to the right. Ensure that an Ocu-Film cover is correctly positioned over the tip with the cardboard ring removed.




2. Point the tip of the Tonopen vertically down, towards the floor.
3. Press the black button twice in quick succession - "CAL" will appear in the display (as shown on the right). Keep the Tonopen still, with the tip pointing at the floor.
4. Within about 15s the Tonopen will beep and the display will change to read "UP".
5. Immediately turn the Tonopen smoothly through 180 degrees so that the tip is now pointing towards the ceiling.
6. If it is functioning properly, it will display "GOOD" and then beep.
7. If "BAD" is displayed, repeat the calibration process.
8. If you are unable to get a "GOOD" reading then try removing the Ocu-Film cover & spraying the sensor tip with compressed air. You can also try replacing the batteries.



#### Measuring the IOP with Either Tonopen Model


1. Explain what you are going to do so that the patient does not become alarmed.
2. Anesthetize the eyes with a drop of local anesthetic.
3. Ensure that the Tonopen has a clean Ocu-Film cover.
4. Roll the Ocu-Film over the head of the Tonopen and remove the cardboard ring. The Ocu-Film should not be loose but neither should it be taught over the tip of the Tonopen. A few folds in the Ocu-Film suggests that it is on correctly (as shown to the right).
5. Give the patient a target to fix on that is straight ahead of them. You can use the Tonopen with the instrument in any orientation (with patients supine or in a chair).
6. Hold the Tonopen so that your index finger is on the button (there is only one button on both models) and rest the heel of your hand on the patient's cheek.
7. Press the button once. It should beep and show "====" (i.e.



a row of double dashes as in the image to the right) in its display. When you see these double dashes you are ready to start checking the IOP.

8. Bring the tip of the Tonopen perpendicularly to the centre of the cornea and touch it gently. You should not indent the cornea at all when doing this - a light touch is all that is needed. It is not painful for the patient.
9. The Tonopen will chirp each time it obtains a measurement. The XL needs 4 measurements to give a reading and the Avia needs 10.

10. A successful measurement will result in the IOP being displayed along with the standard deviation of the readings (you should have a bar next to 5% in the display, indicating that all readings were closely grouped). The image to the right shows a reading of 9mmHg with an SD < 5%.



11. The IOP is usually < 20mmHg and the two eyes usually have IOPs that are within 5mmHg of one another.
12. To take another measurement, simply press the button once and start again (be sure to make a note of your first reading - the readings are not saved).
13. If you see a line of single dashes ("--- ") then you did not get a measurement.
14. Always check the IOP in both eyes (no need to change the Ocu-Film, unless there is a concern about infection), so that you can compare one reading to the other.
15. When finished, discard the used Ocu-Film cover and replace with a new one, leaving the cardboard ring in place (so the next user knows that it is clean).

## Using an iCare Tonometer

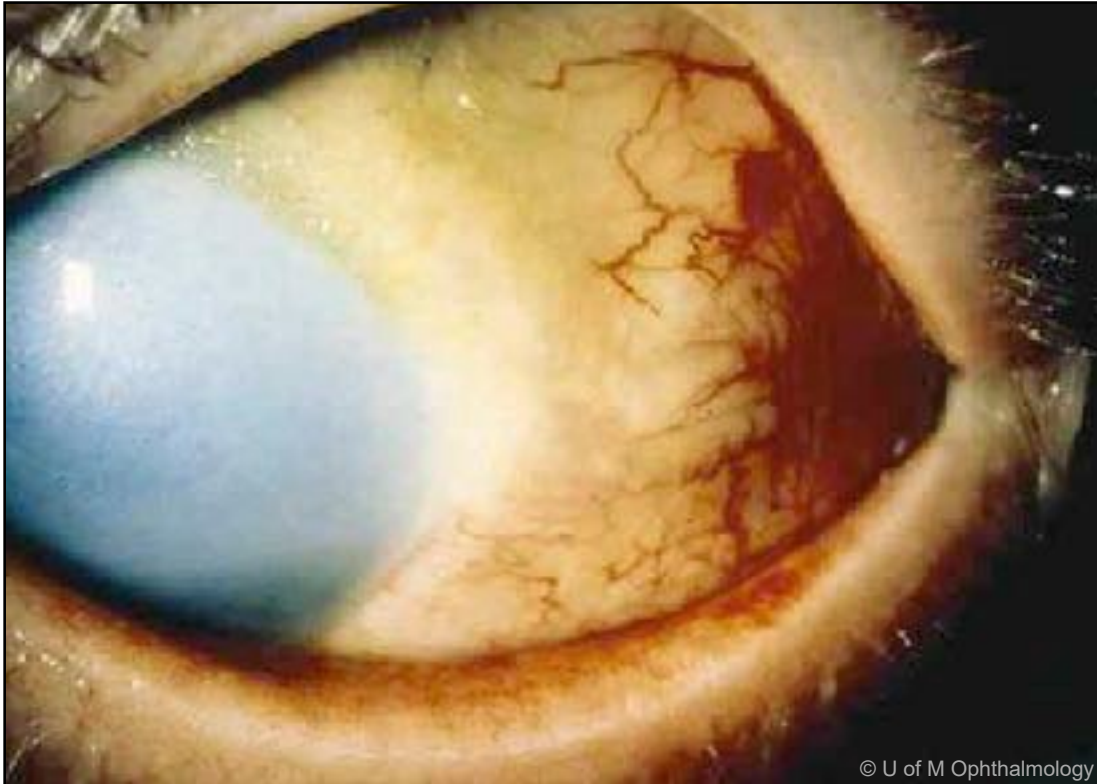Some Emergency Departments have an [iCare tonometer](#). This is another digital device for checking the intraocular pressure that can get an accurate reading with very little training. There are [online videos](#) that explain how to use it.



## Image Gallery

The following images have been selected to be representative of common pathologies. They are best viewed electronically. Please do not reproduce these images without permission.

Serious [chemical injury](#) with ischaemia:

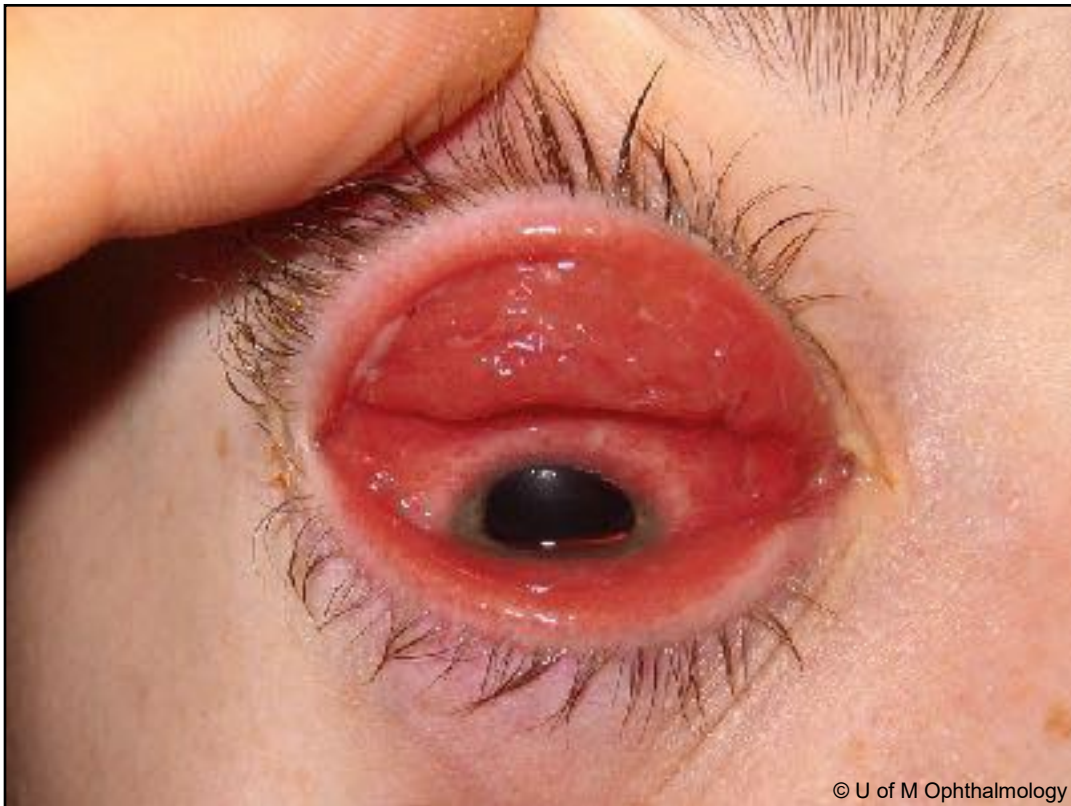

The cornea is opaque and the blood vessels over the white of the eye have been obliterated over a large area, indicating ischemia and a serious injury (hyperemia, by contrast, is a good sign after a chemical injury).

Blepharitis:

No good image currently available to us. There is a representative image and diagram on the [Johns Hopkins](#) web site.

Follicular conjunctivitis as seen with [viral infections & chlamydia](#):



© U of M Ophthalmology

Follicles are seen with

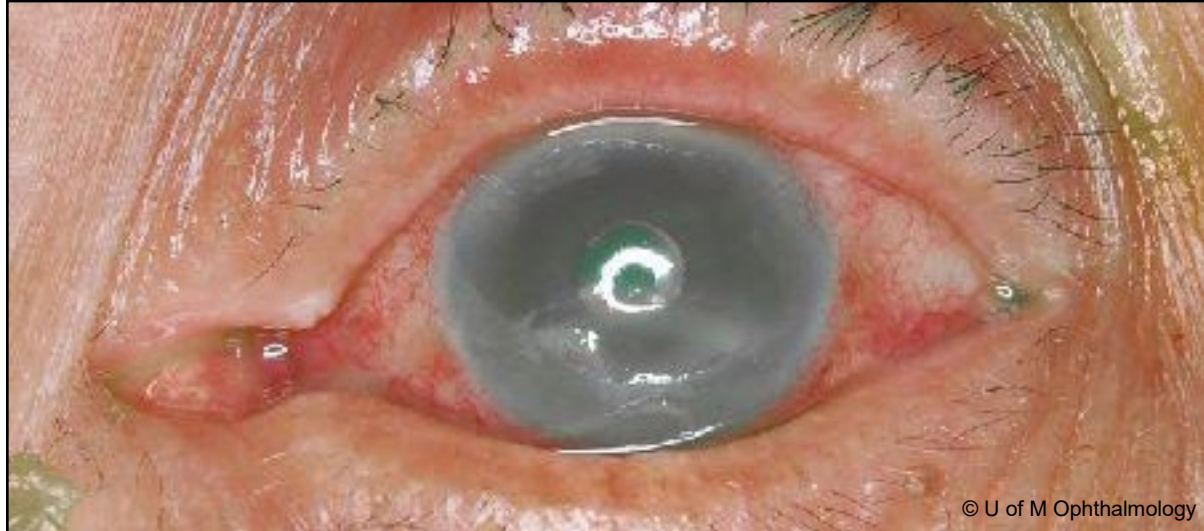- viral conjunctivitis
- chronic allergic conjunctivitis
- hypersensitivity to topical medications and
- chlamydial conjunctivitis

This patient had chlamydia, and this is an example of a very intense follicular conjunctivitis. The patient had been treated with numerous drops for infection and allergy, but nothing helped. A chlamydia swab was positive.

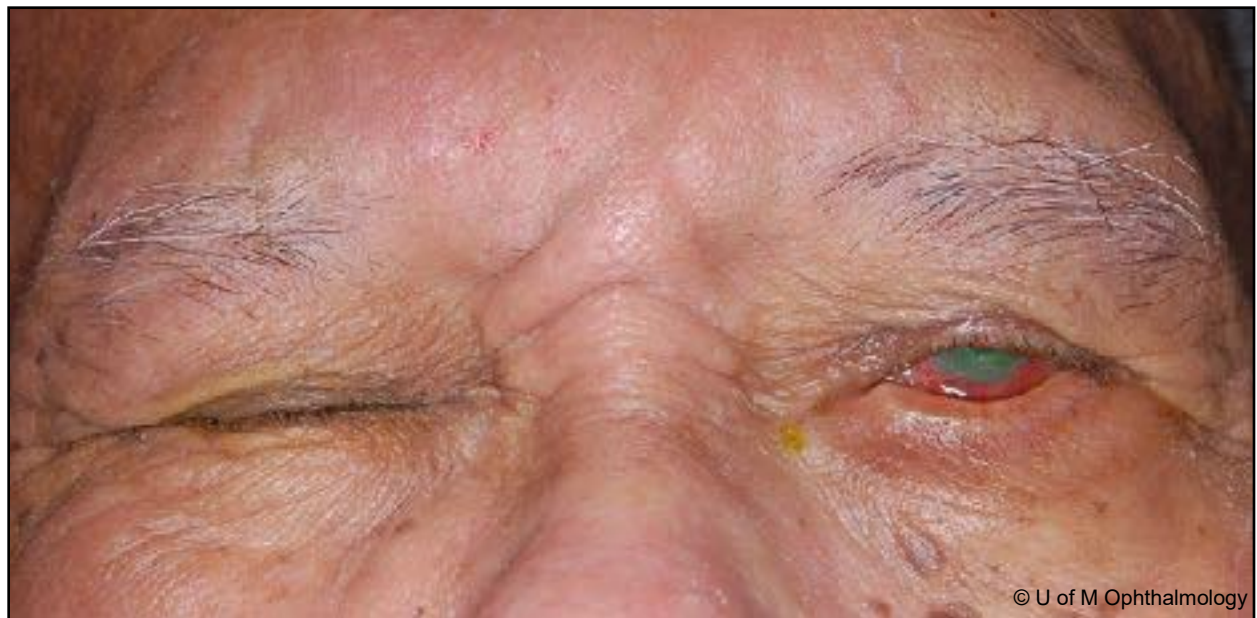
Patients with chlamydia conjunctivitis should be seen by a public health service for contact tracing. The treatment is not with eye drops - they need systemic tetracyclines.



Exposure keratopathy secondary to VII paresis

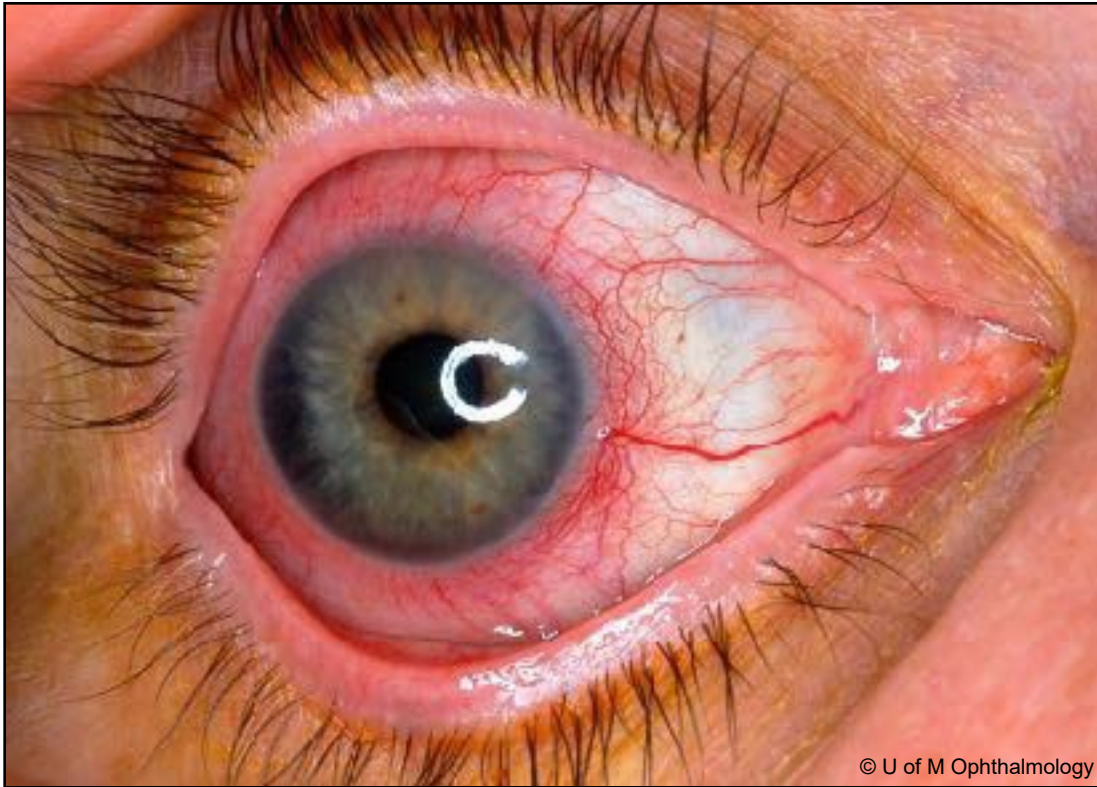

Here you can see the rough edge of a large ulcer on the inferior third of the cornea. The chronically exposed inferior cornea has a misty-white haze to it, and the eye is injected as well. Fluorescein will stain the ulcer.



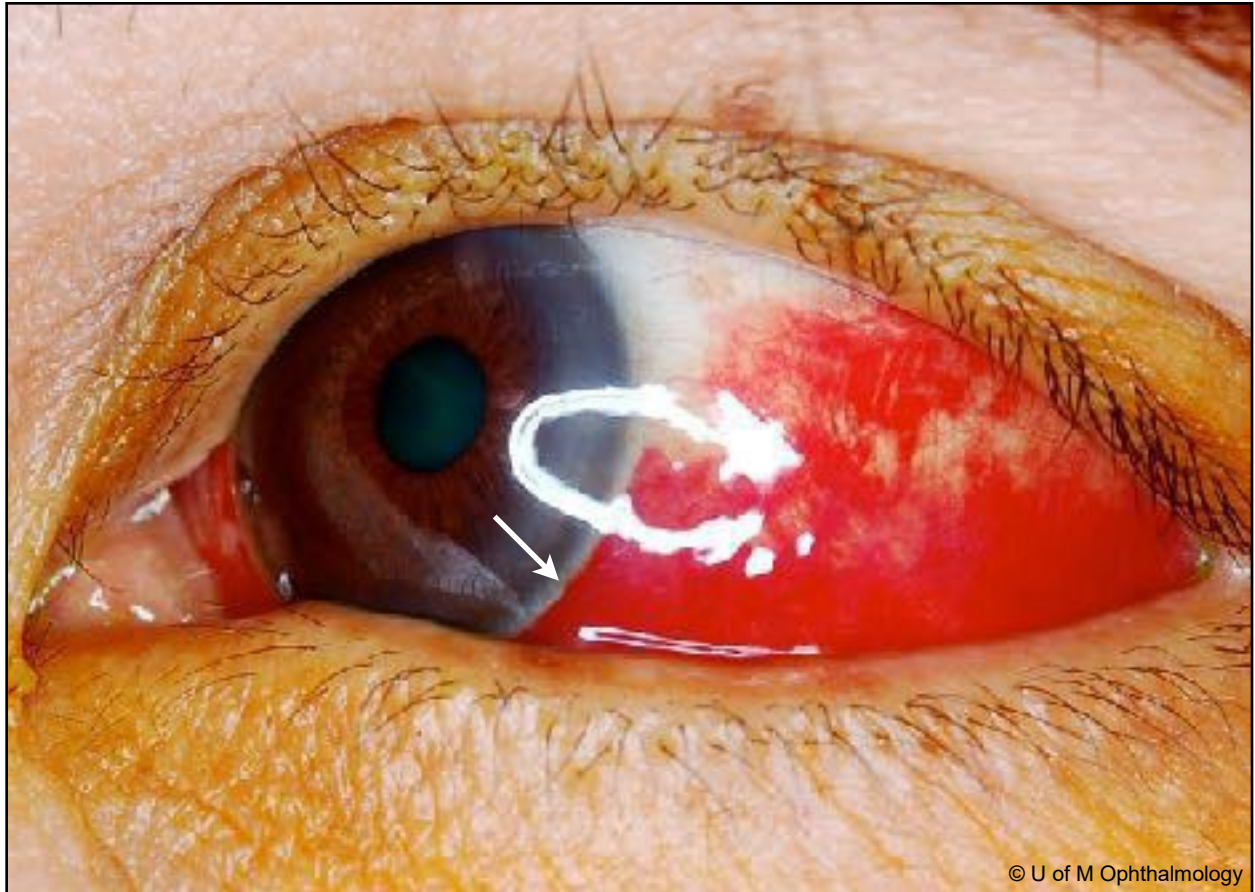This is the same patient trying to close both eyes. The left LMN VII paresis results in lagophthalmos and chronic exposure. Prescribe lubricating ointment to protect the cornea (such as *ung. Refresh Lacri-Lube*). Advise patient to use it liberally, at least 6 times a day. They can also tape their eyelid shut, or wear swimming goggles to prevent drying.

## Ciliary injection in anterior [uveitis](#)



In anterior uveitis the anterior part of the uvea is inflamed: the ciliary body and iris. This so-called ciliary injection is due to inflammation of the ciliary body, which is situated beneath the sclera, just posterior to the limbus. There is little, if any, inflammation seen over the sclera more posteriorly (and the conjunctival fornices will not be inflamed either, in contrast to what you would see in an infectious conjunctivitis where the fornices are maximally inflamed).

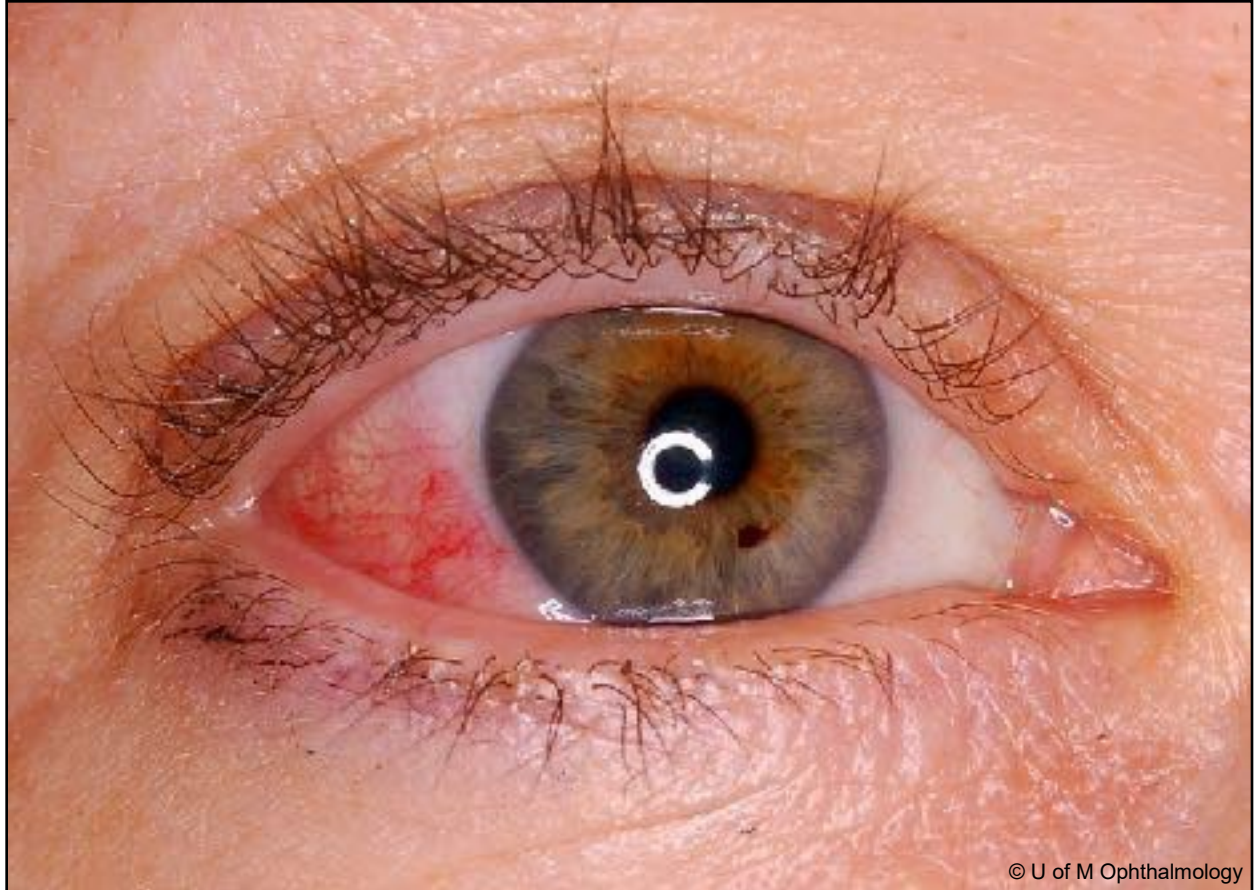Subconjunctival hemorrhage (ignore the c-shaped white reflection from the camera flash):



There is confluent blood beneath the conjunctiva. Note how it stops abruptly at the limbus (indicated with the arrow), where the conjunctiva ends. There are no dilated blood vessels visible over the remainder of the eye, indicating the absence of any inflammatory process.



Episcleritis:



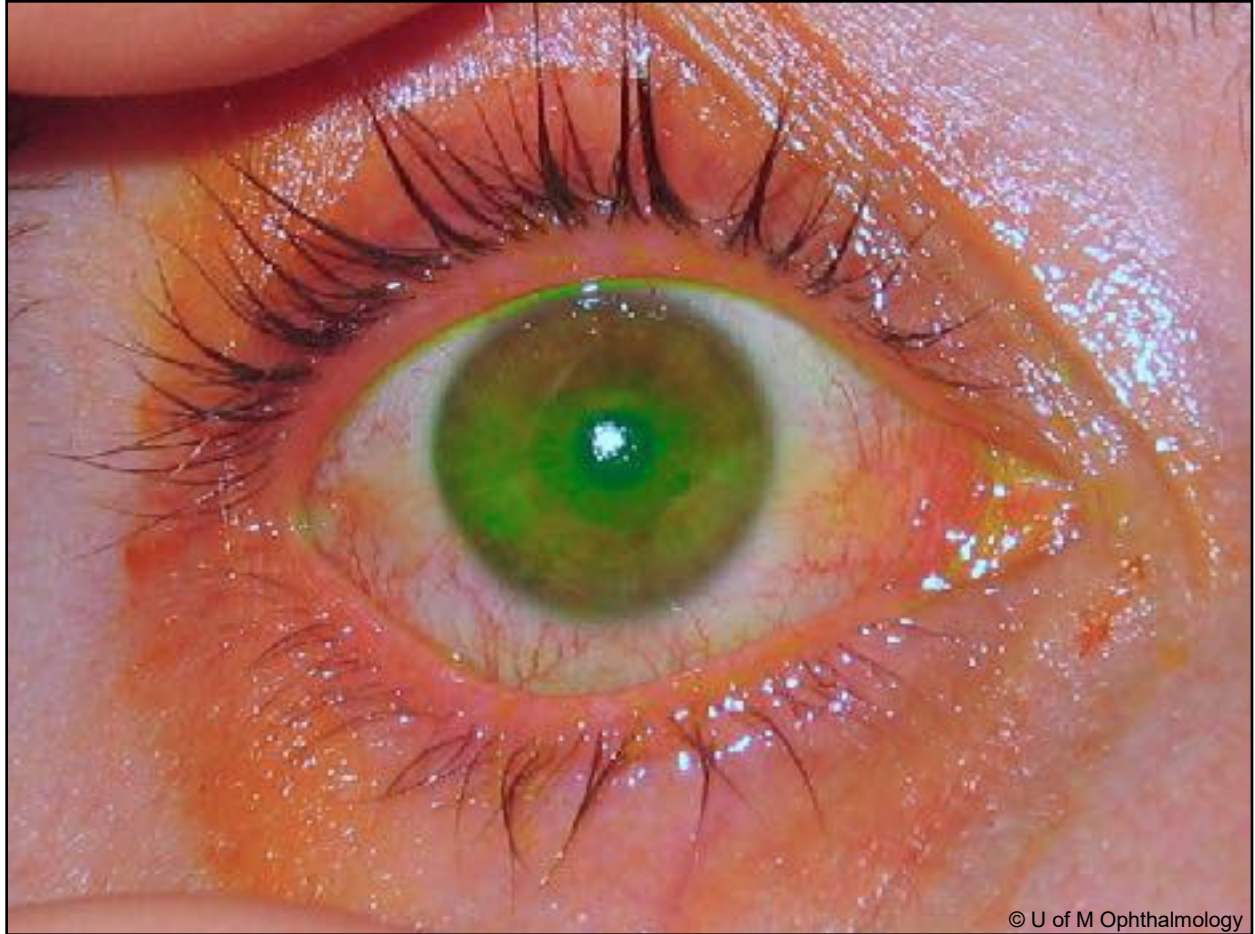This is a very characteristic appearance, with injection that usually only involves one half of the eye (either the nasal or temporal conjunctiva). There may be a history of previous episodes, and it is usually young adults who are affected.

Vision is unaffected, there is no discharge and the condition causes minimal discomfort (usually a slight irritation). Patients are nonetheless usually very anxious, as the eye is red.

Occasionally you may see a small nodular elevation in the injected area.

If it is irritating, then an artificial tear drop (used sparingly) can be helpful, but it is self-limiting and will usually resolve spontaneously after a month or so.

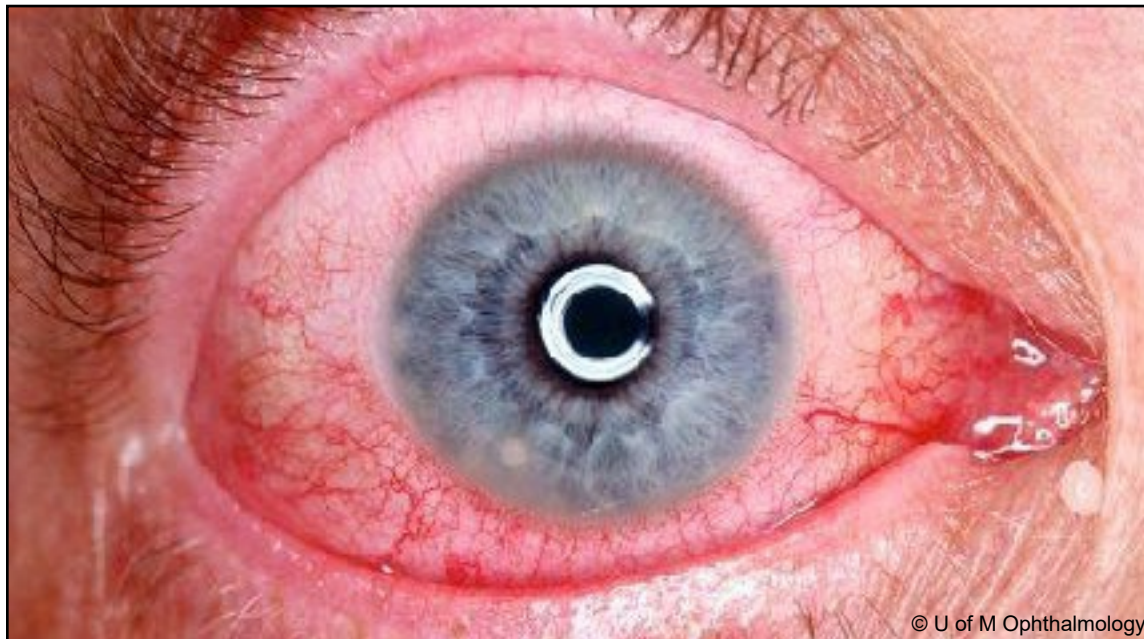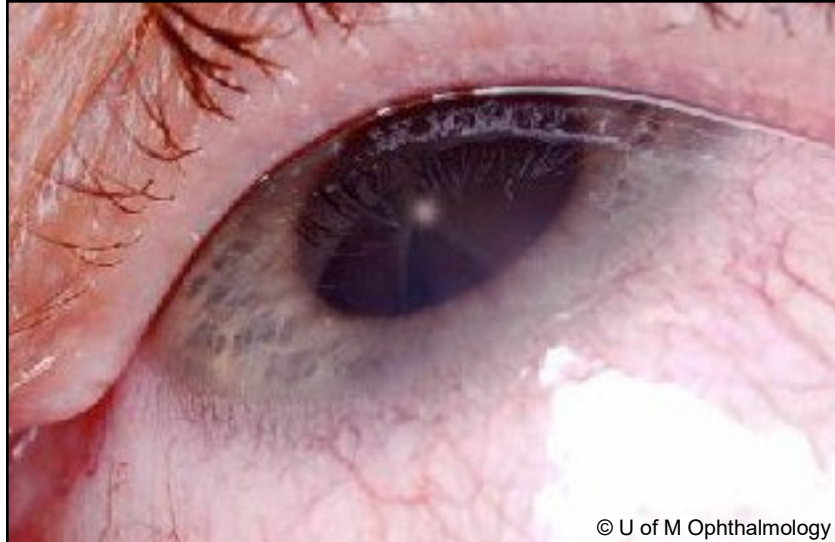Arc eye (thermal, or ultraviolet keratopathy):



A band of fluorescein staining and conjunctival injection is present over the central portion of the cornea and conjunctiva (there is no staining over the upper and lower parts of the globe where the eyelids were shielding the eye at the time of exposure).

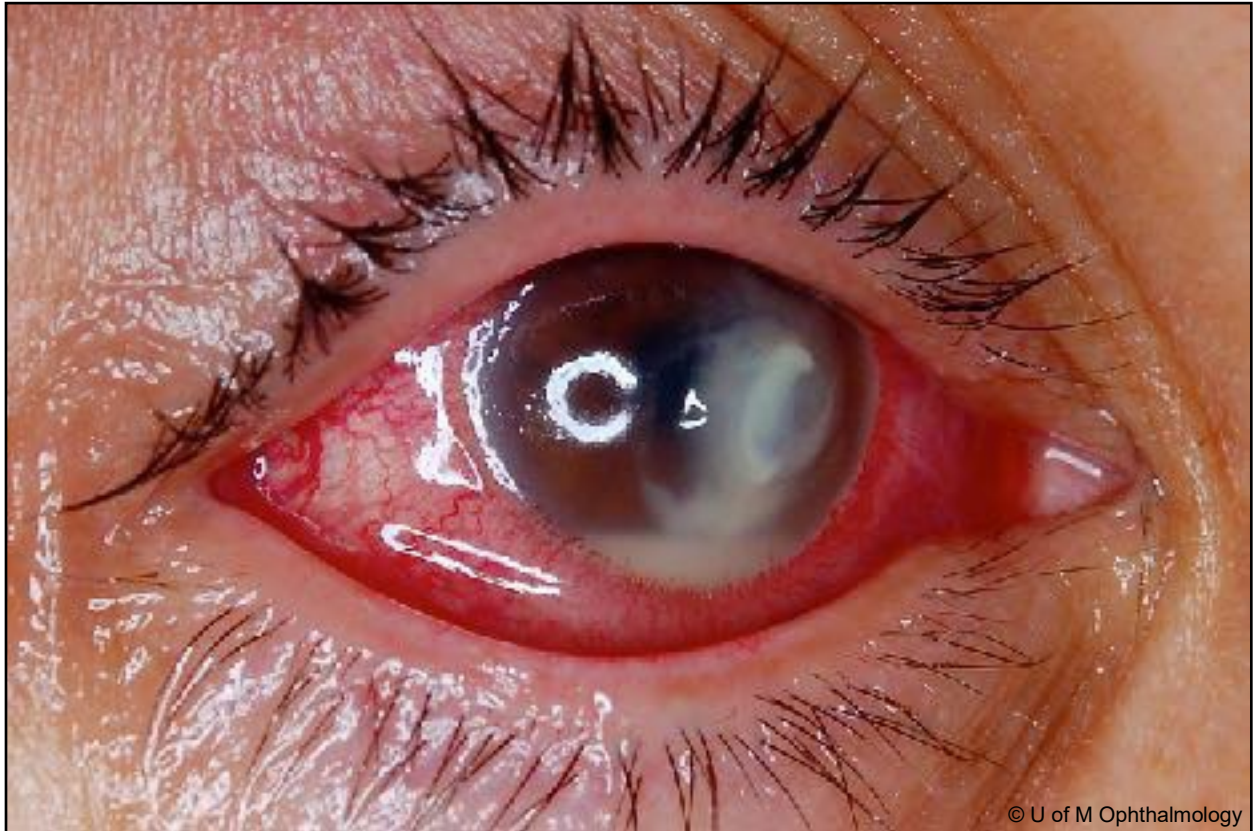
Bacterial keratitis:

3 images follow, each representing an increasingly severe infection. In this top image there is a very small (~1mm diameter) creamy-white “infiltrate” over the centre of the pupil.



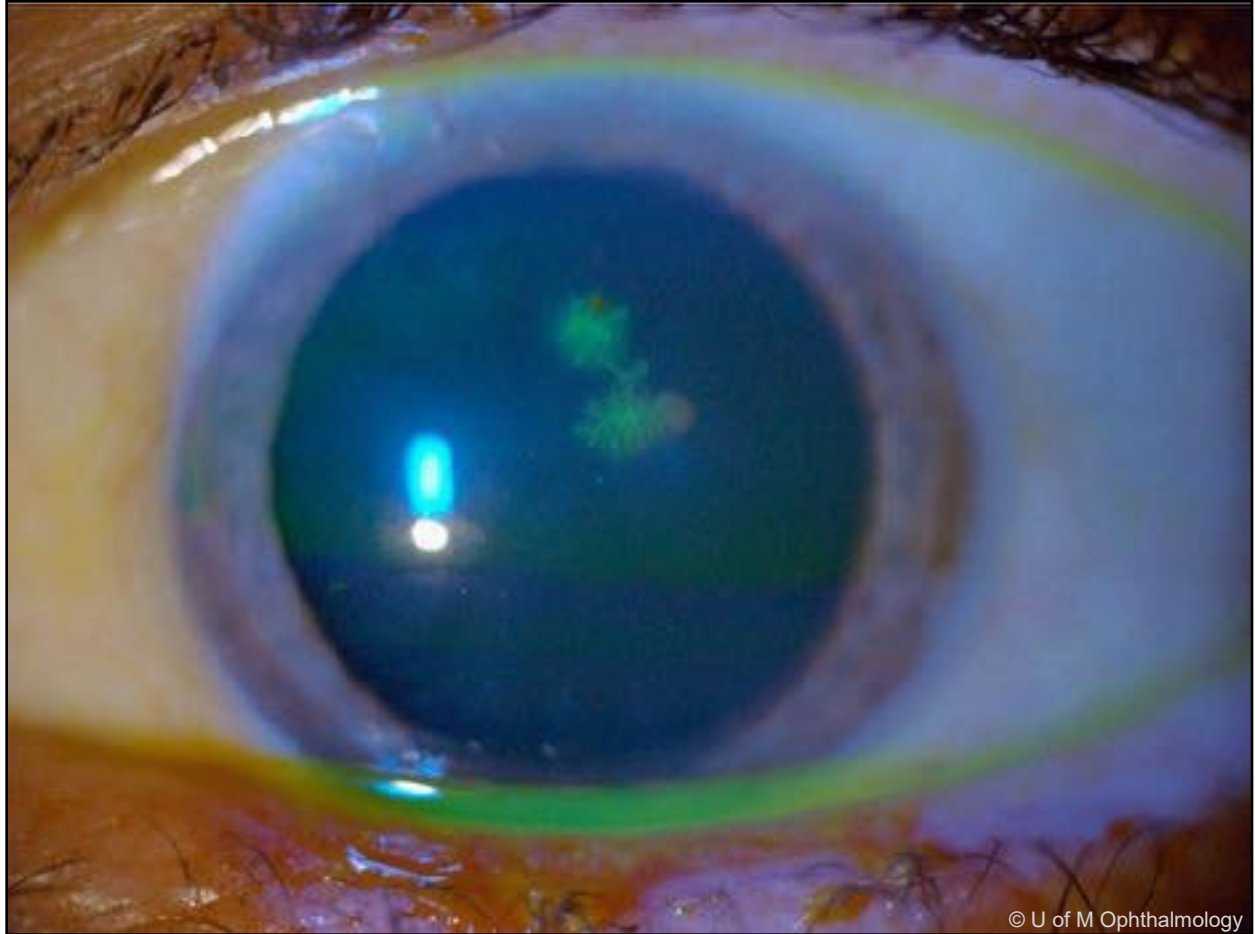In the image above, the infiltrate is near the limbus at the 7 o'clock position. It is about 2mm in diameter, and this eye is much more injected over the adjacent conjunctiva due to a more established corneal infection.





This is a very severe necrotising corneal ulcer with such a severe inflammatory response that a hypopyon is visible. The eye is very red and painful, and the vision is severely reduced. This requires admission for very intensive treatment with round-the-clock, fortified antibiotic eye drops in order to prevent perforation of the cornea and loss of the eye.

Herpes simplex keratitis:



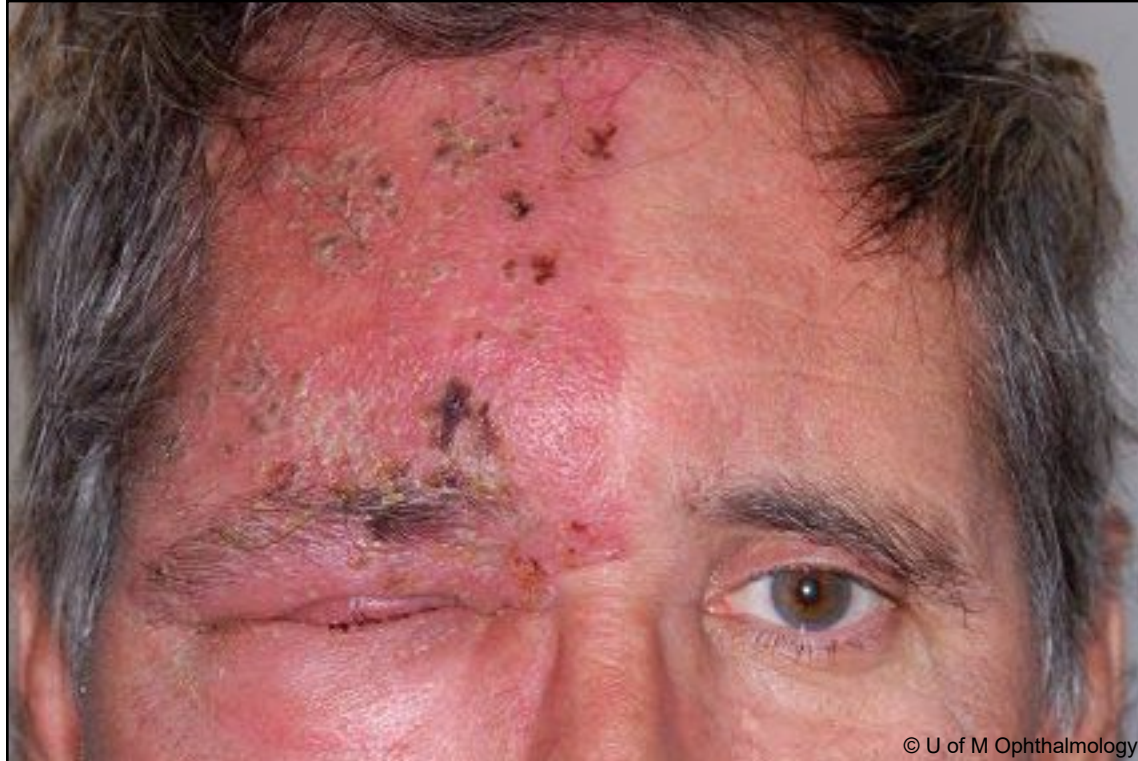This is a pathognomonic appearance for a herpes simplex keratitis. Note the branching pattern of the ulcer with club-shaped terminal bulbs. Lesions may be smaller, or much larger, depending on the length of the history.

Vision may be unaffected, or mildly reduced, and the patient will complain of a sharp pain or FB-sensation. There will be no discharge, though the eye may water at times.

This can be a recurrent condition (just as with cold sores).



[Herpes zoster ophthalmicus:](#)

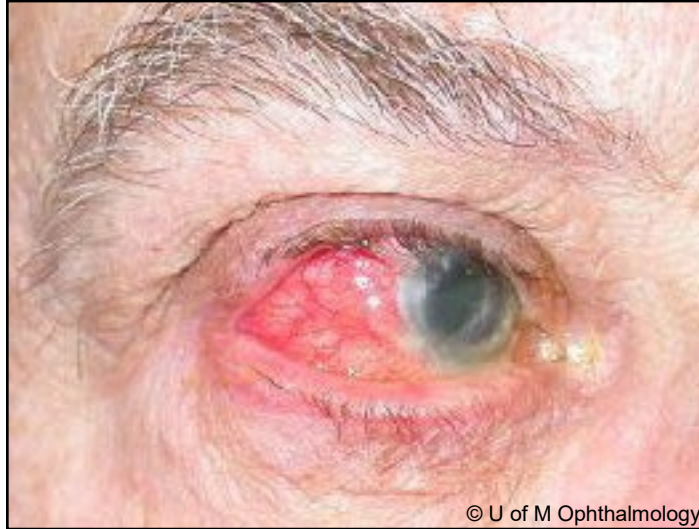

15% of all cases of herpes zoster affect the 1st division of the trigeminal nerve; these cases are known as herpes zoster ophthalmicus. The rash is no different to that seen on other dermatomes (as are the symptoms). It is important to recognize that the severity of the rash can be very variable, with only a few vesicles in some cases. The rash characteristically stops at the midline of the face, but bacterial superinfection (leading to a cellulitis) is not uncommon, in which case the erythema may spread across the midline.

The eyes can be affected in a variety of ways, but all cases are preceded by cutaneous involvement. Superficial involvement of the eye is self-limiting and harmless, however 40% of cases of HZO will develop intraocular inflammation, so all patients should be referred.

The so-called Hutchinson sign (vesicles on the ipsilateral side of the nose) does increase the risk of intraocular inflammation, but its absence does not rule out this possibility (so it is not a clinically helpful sign).

### Scleritis:

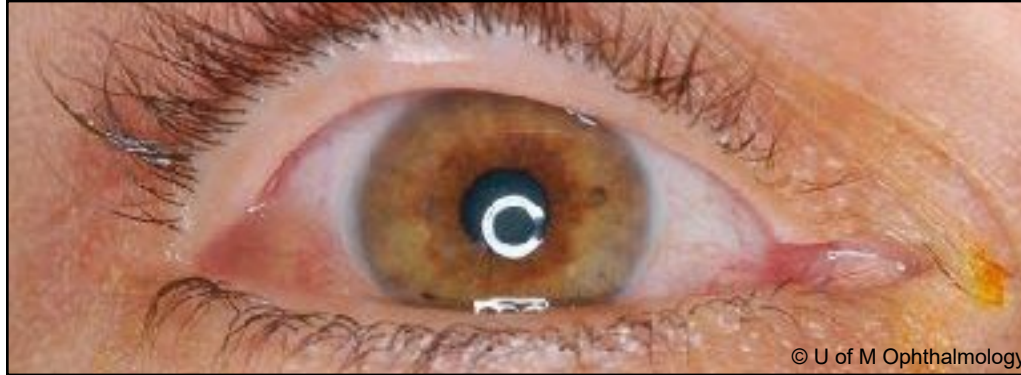

This eye is very injected and very tender due to scleritis. The pain is usually sufficiently severe to disturb sleep. It may radiate to the forehead, brow or jaw. Vision is usually reduced. The vessels over the sclera are very dilated and will not blanch with topical *phenylephrine*.

The inflammation may cause thinning of the sclera to the extent where a hole may develop in the eye (a scleral “melt”). This makes the affected area look darker (blue or black) due to exposure of underlying pigmented uveal tissue.

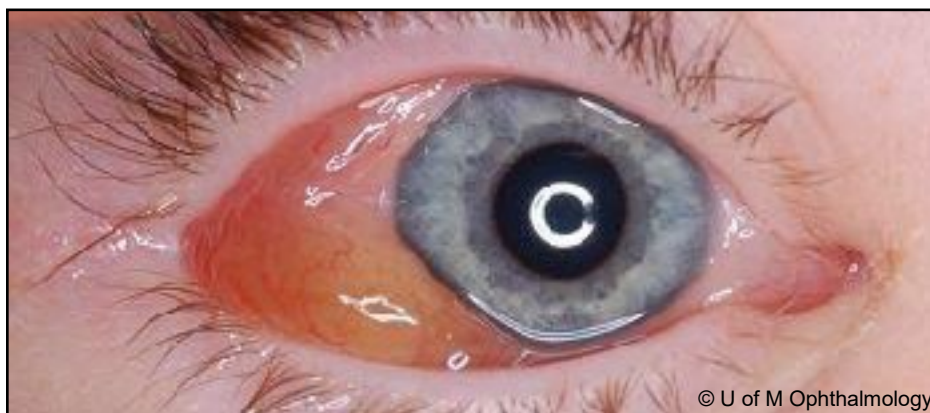50% of cases have an associated systemic disease, usually a connective tissue disease such a granulomatosis with polyangiitis (Wegener granulomatosis) or rheumatoid. Some cases are associated with herpes zoster ophthalmicus or other infectious etiologies.

Chemosis seen in [acute allergic conjunctivitis](#):

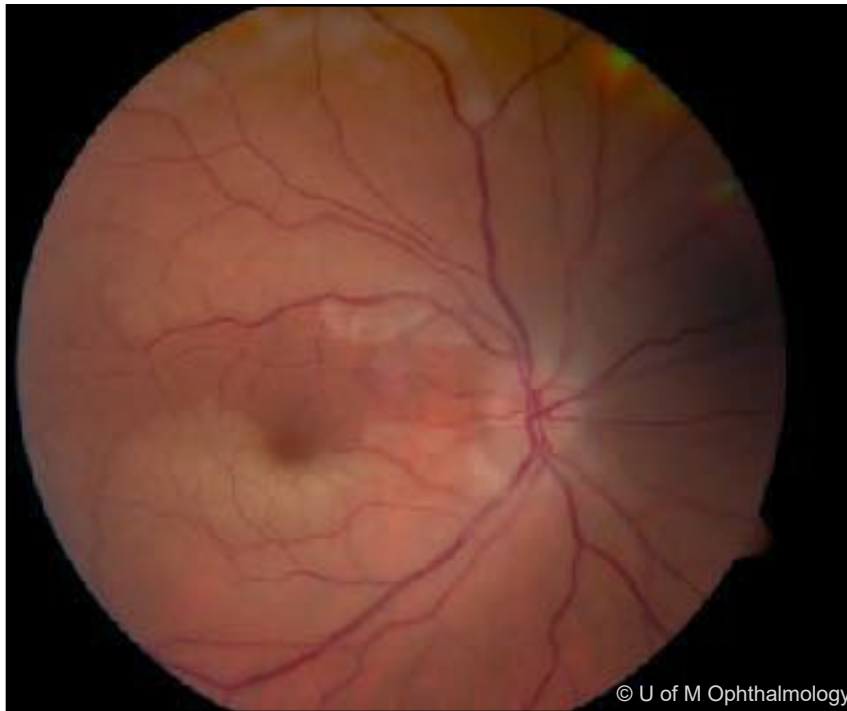

There is a gelatinous appearance to the lower temporal conjunctiva. This is caused by a type 1 hypersensitivity reaction, with mast cell degranulation causing acute edema beneath the conjunctiva. It is caused by a sensitized individual contacting a specific allergen. The eye or eyes feel very itchy (characteristic of allergic eye disease). The eye may water, but the vision is unaffected, and there is minimal redness. Cold compresses are usually all that is needed. The symptoms and signs will settle within hours. Oral antihistamines may also be prescribed.

Chemosis is also seen in cases of [orbital inflammation](#). As the underlying cause is inflammatory, there will be more injection and the eye will look red (as in the image below). There may be other signs of orbital disease (proptosis, limitation of eye movements, reduced vision, diplopia, pain...).



Central retinal artery occlusion (CRAO) on fundoscopy:

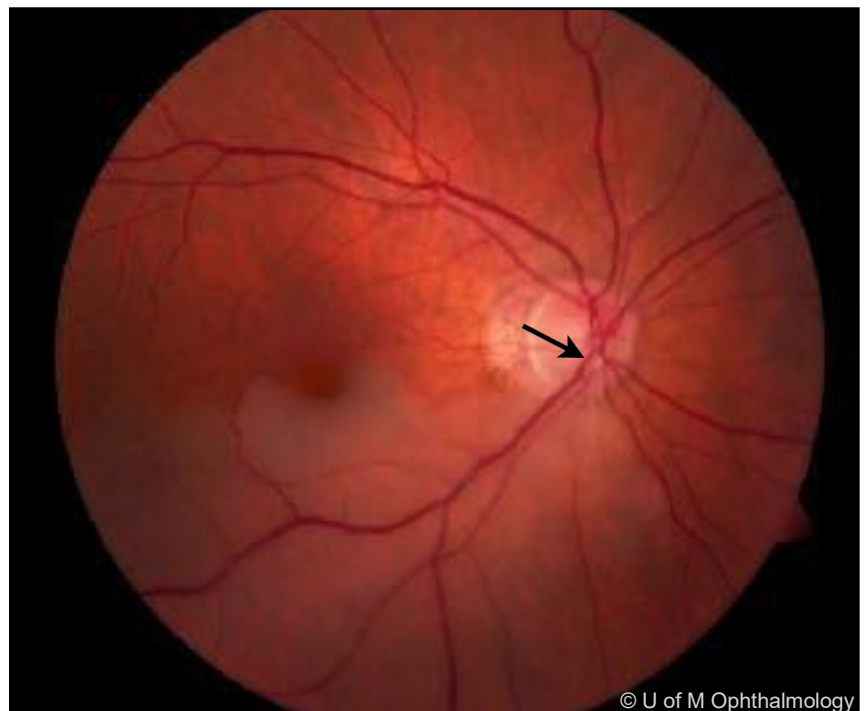

The retina will look pale in an acute CRAO, with all vessels demonstrating reduced diameter due to lack of perfusion. If there is any doubt then compare the appearance of the retina with that of the normal eye.

Typically you would expect to see the fovea as a bright “cherry-red” spot (as the underlying choroidal circulation is

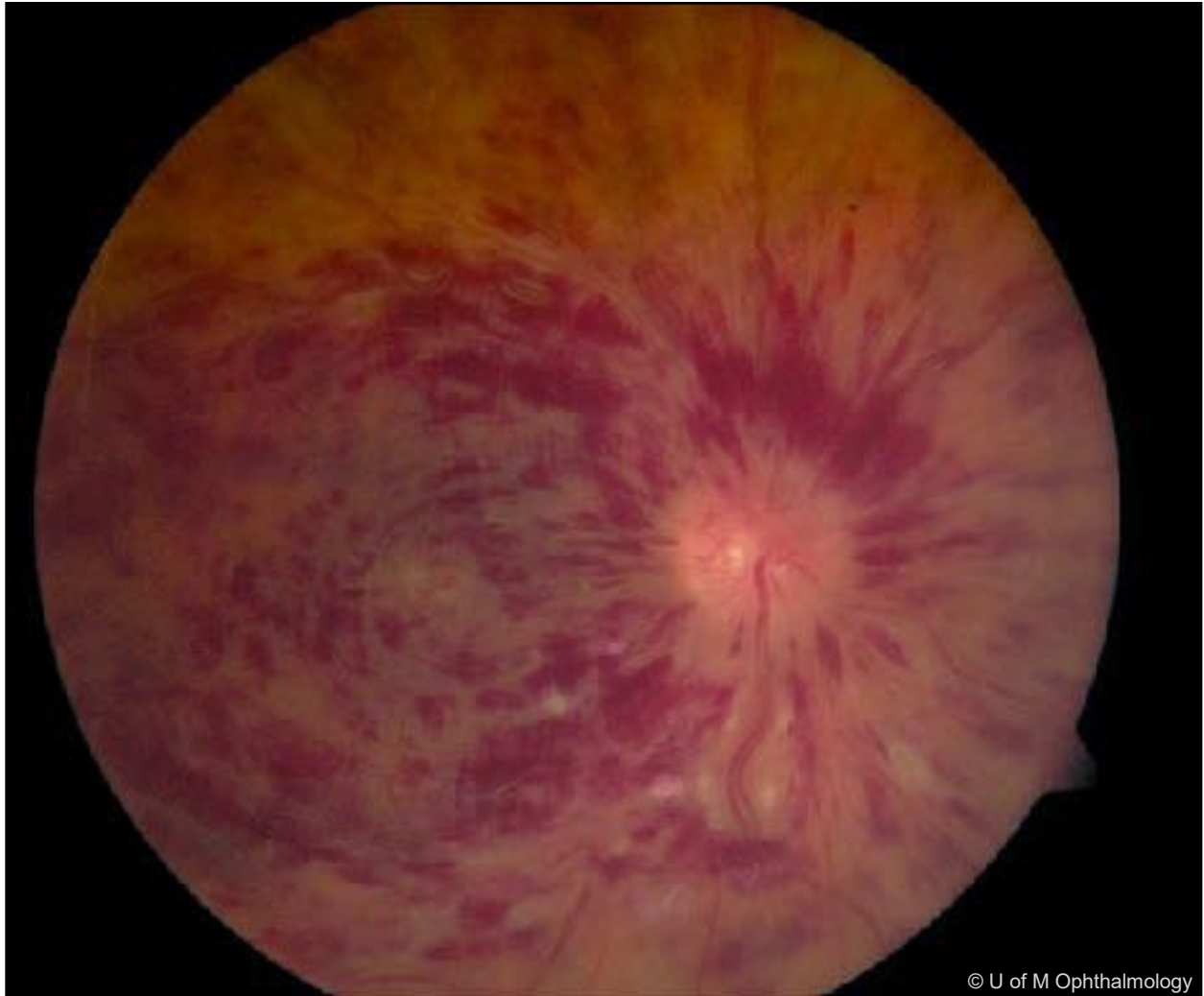
more apparent through the thin retina in this part of the eye). The veins may have a discontinuous column of blood within their lumen giving them a beaded appearance in some cases.

The image to the right shows a yellow embolus in an artery at the disc (marked with the arrow) that has occluded the blood supply to the inferior retina. As a result, the inferior retinal arterioles are attenuated and the inferior retina is pale and edematous. This patient will predominantly complain of a *superior* visual field loss.





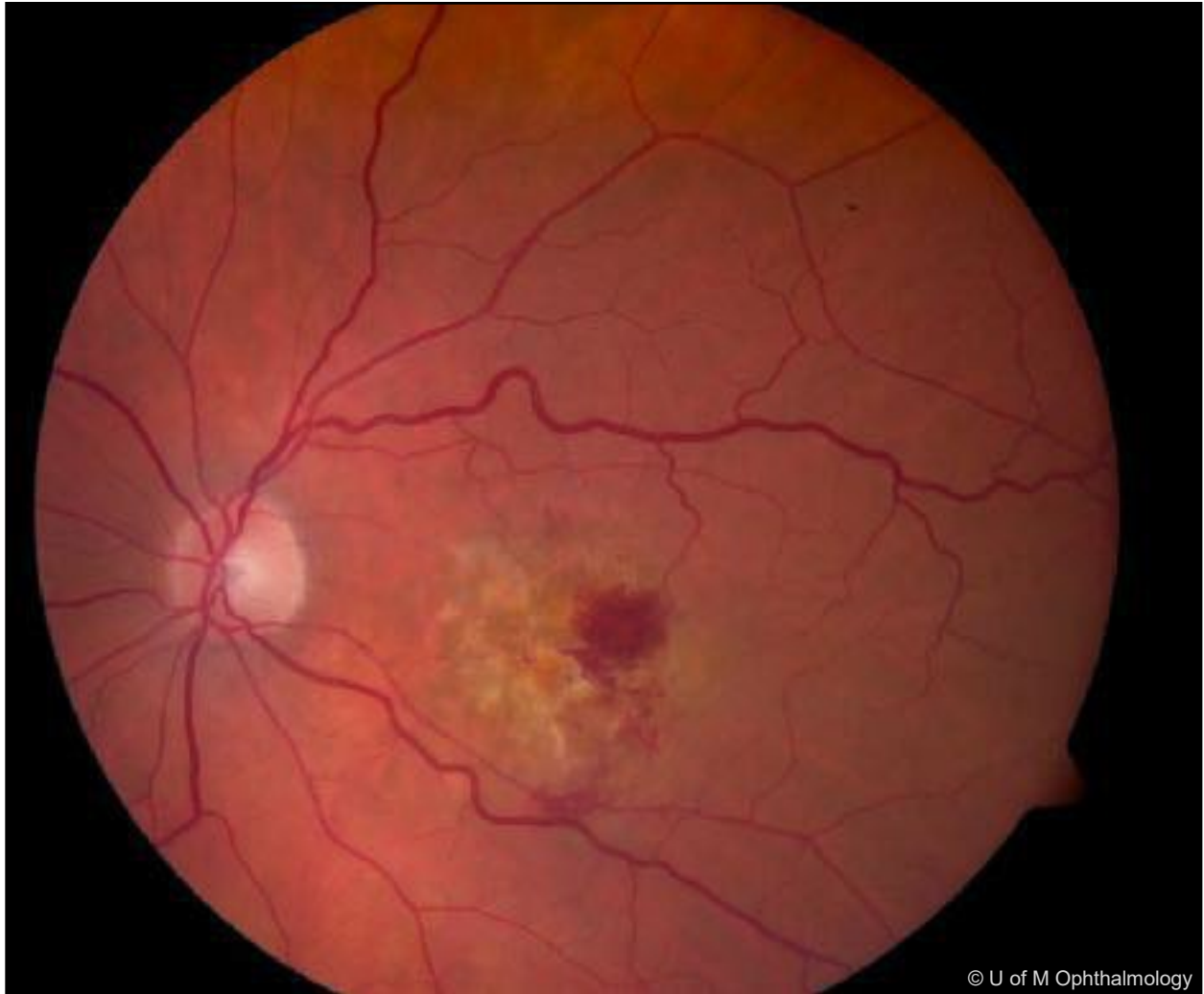Central retinal vein occlusion:



The photo shows a swollen optic disc with multiple flame-shaped retinal hemorrhages in all 4 quadrants, and cotton-wool spots (which are a sign of ischemia).

Note that it is possible to have an occlusion of a branch retinal vein that affects a smaller area of the retina (upper or lower half of the retina, or even a smaller branch that just involves the macula).

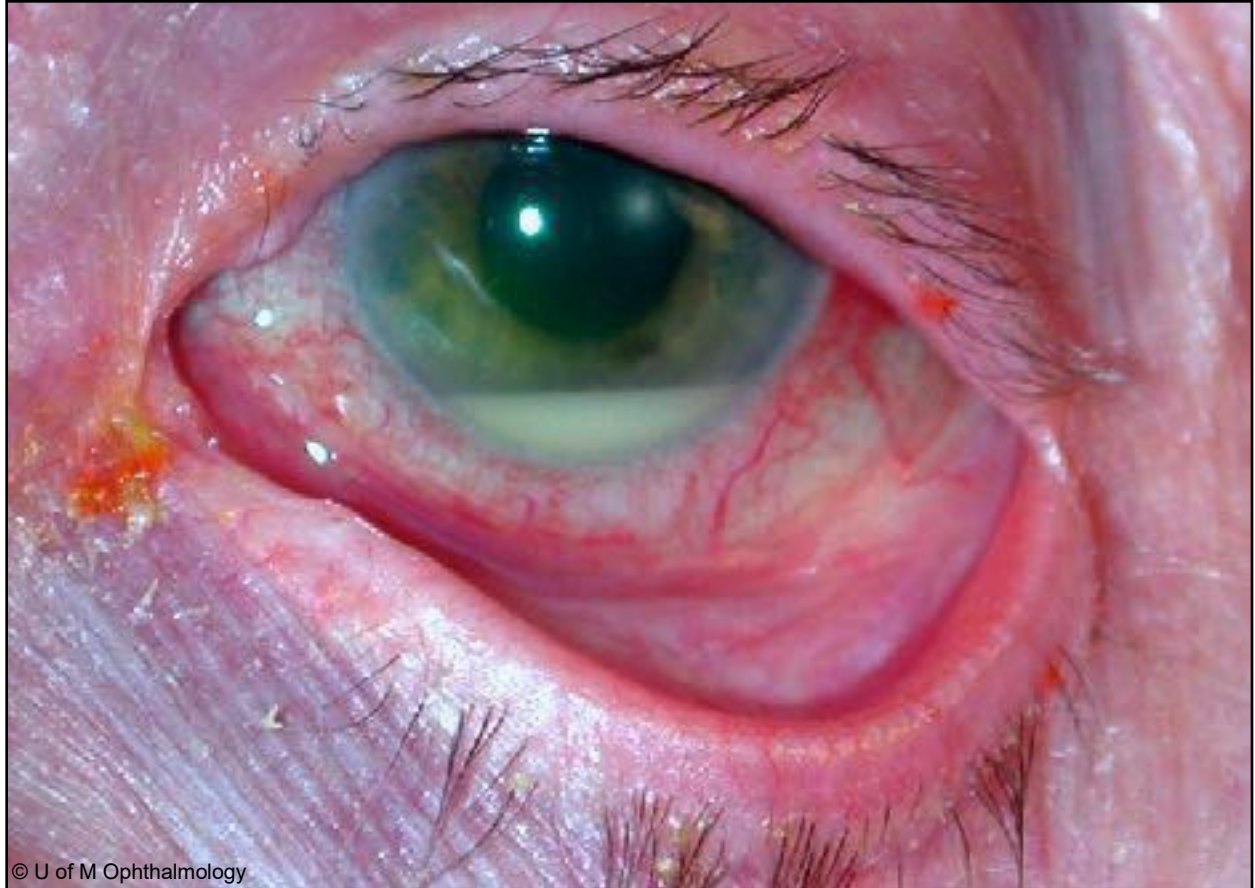Macular degeneration:



This photo shows drusen (yellow intraretinal lesions) at the macula with associated intraretinal hemorrhages. An acute bleed at the macula will lead to reduced vision.

It is worth noting that macular degeneration does have a very heterogeneous appearance but the variation in color and/or pigmentation of the retina in the macular area are universal findings.

Endophthalmitis with a hypopyon:



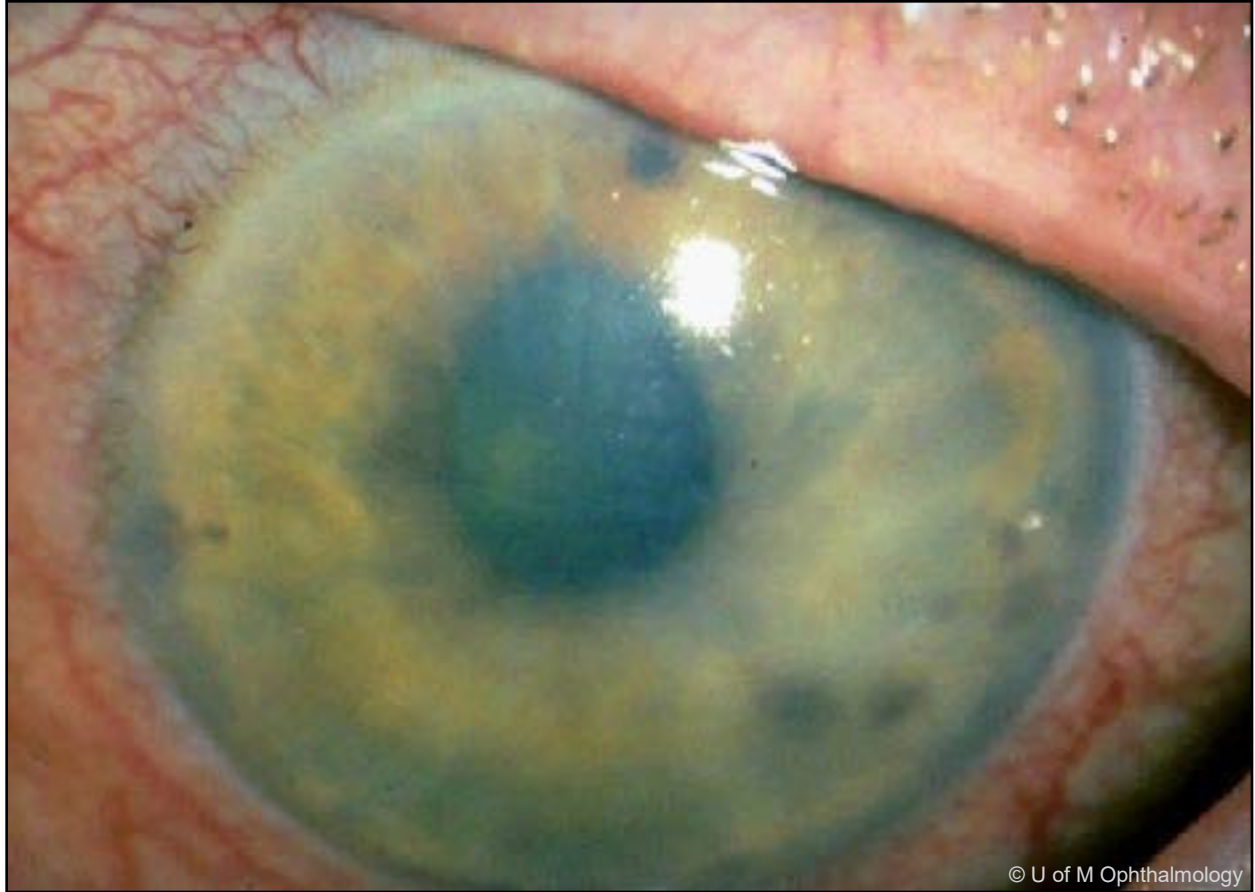The lower eyelid is being pulled down in this photo to show the creamy-white fluid level in the anterior chamber. This appearance is caused by white blood cells settling in the inferior angle of the anterior chamber.

This patient had undergone an intraocular surgery a few days prior to presenting with reduced vision, increasing redness, and increasing pain. It is a sign of intraocular infection, which is a serious complication that must be dealt with urgently.

It can also be seen after intraocular injections (e.g. for macular degeneration), when it is also likely to be infectious.

Some patients with a severe endogenous uveitis (e.g. HLA-B27-related) can present with a spontaneous sterile uveitis that can look just like this.

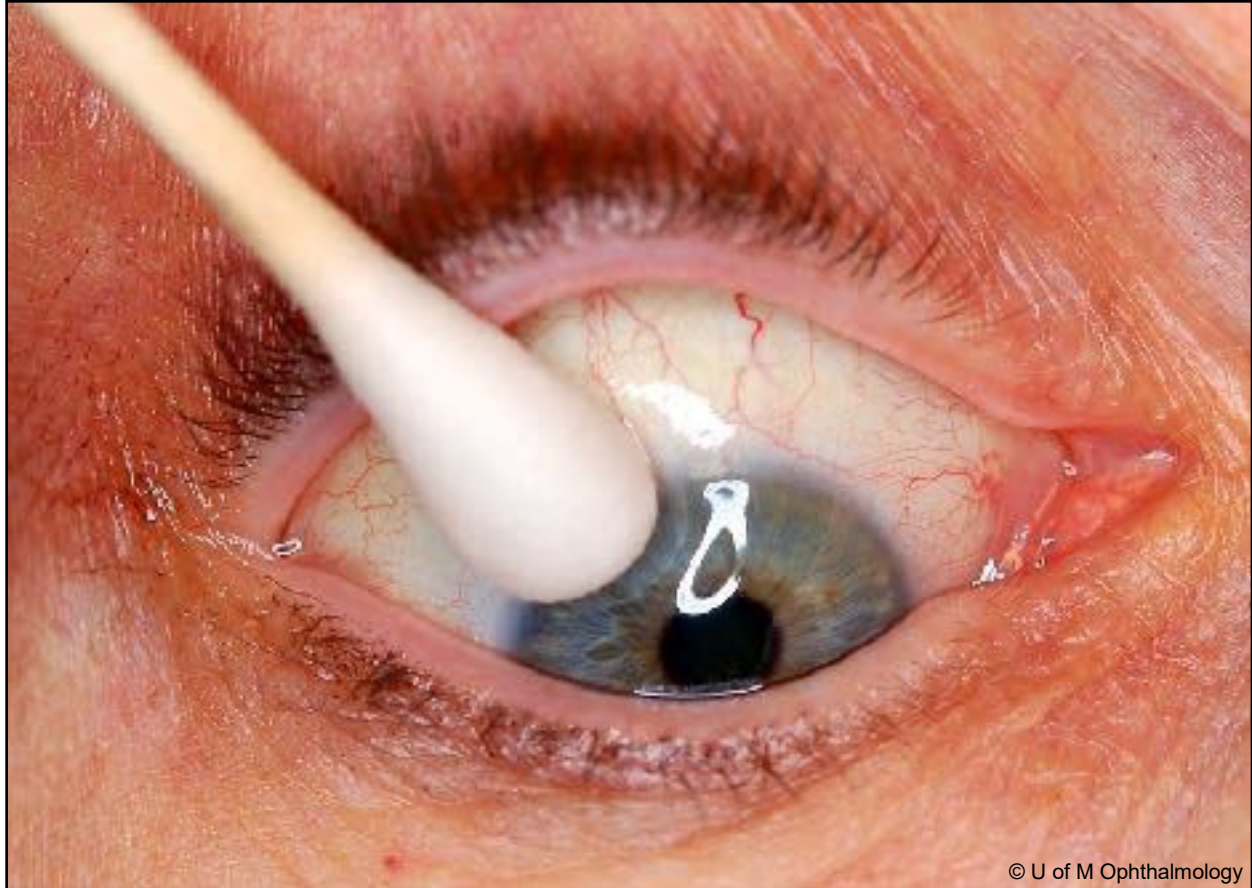
Acute angle closure glaucoma:



The eye is red, the pupil is fixed and slightly dilated. Due to the acute rise in intraocular pressure, the cornea has become edematous (making it hazy), so details of the iris and pupil are hard to see. If you are unable to check the intraocular pressure with a device like a Tonopen then it is still possible to make an assessment of the pressure by pressing on the eye through the upper eyelid. The globe is normally firm to palpation, but you can indent it with firm pressure (feel the other eye, or your own). An eye with acute glaucoma will be hard by comparison.



Massaging the eye with a cotton-tipped applicator to treat acute angle closure glaucoma:



You can see that the limbus and cornea are being distorted by the pressure that is applied with the cotton-tipped applicator. This can open a channel for aqueous to escape through the trabecular meshwork, thereby breaking the acute attack. It is important to do the massage in short bursts so that blood flow can be re-established in the breaks (massage will make the intraocular pressure very high, stopping arterial flow).

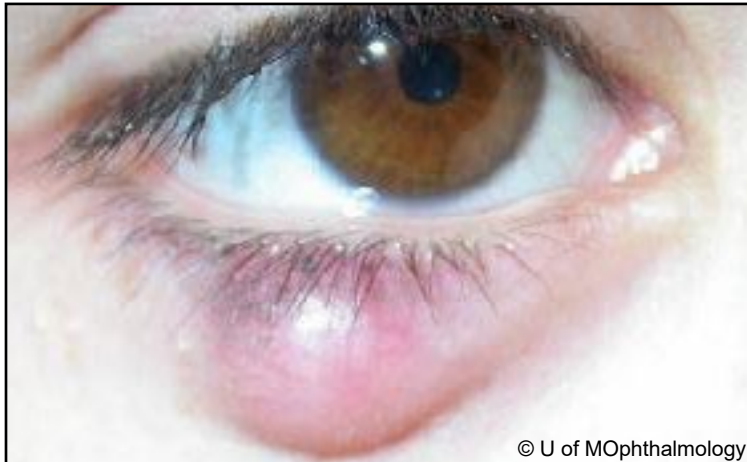If this doesn't break the cycle you can massage more centrally on the cornea (mid-periphery, or directly over the pupil). By physically making the center of the anterior chamber more shallow, aqueous will be displaced peripherally and this can open up the angle. You may see the pupil edge move if you are successful with this technique but the real test is a reduction in measured intraocular pressure, & an improvement in symptoms.

Massage directly on the cornea can cause a corneal abrasion, but this is a transient inconvenience in an eye that is already very painful (compared to possible permanent visual loss from refractory angle closure glaucoma).

### Chalazion:

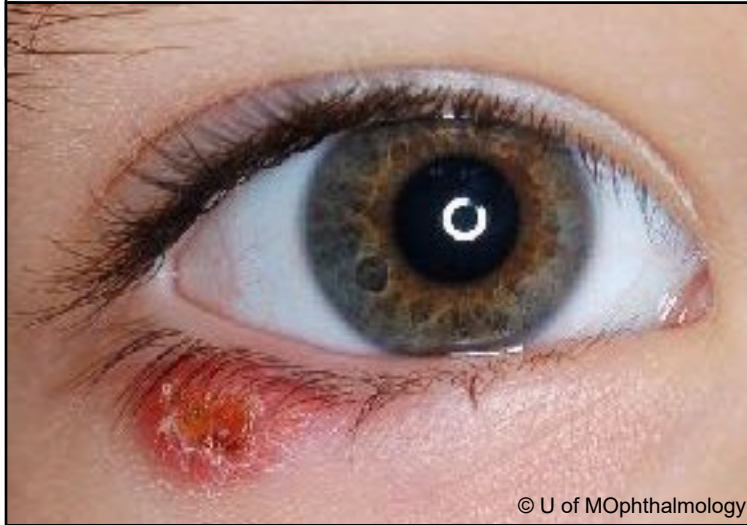These benign lesions arise within the meibomian glands of the eyelids. They are most common in children and young adults. They typically slowly enlarge, and eventually disappear spontaneously. They may wax and wane somewhat before disappearing.

Some lesions may cause chronic granulomatous inflammation; this will result in inflammation of the cyst and surrounding eyelid. This usually precipitates resolution, but some patients may be left with a granuloma that may need to be removed.



© U of M Ophthalmology

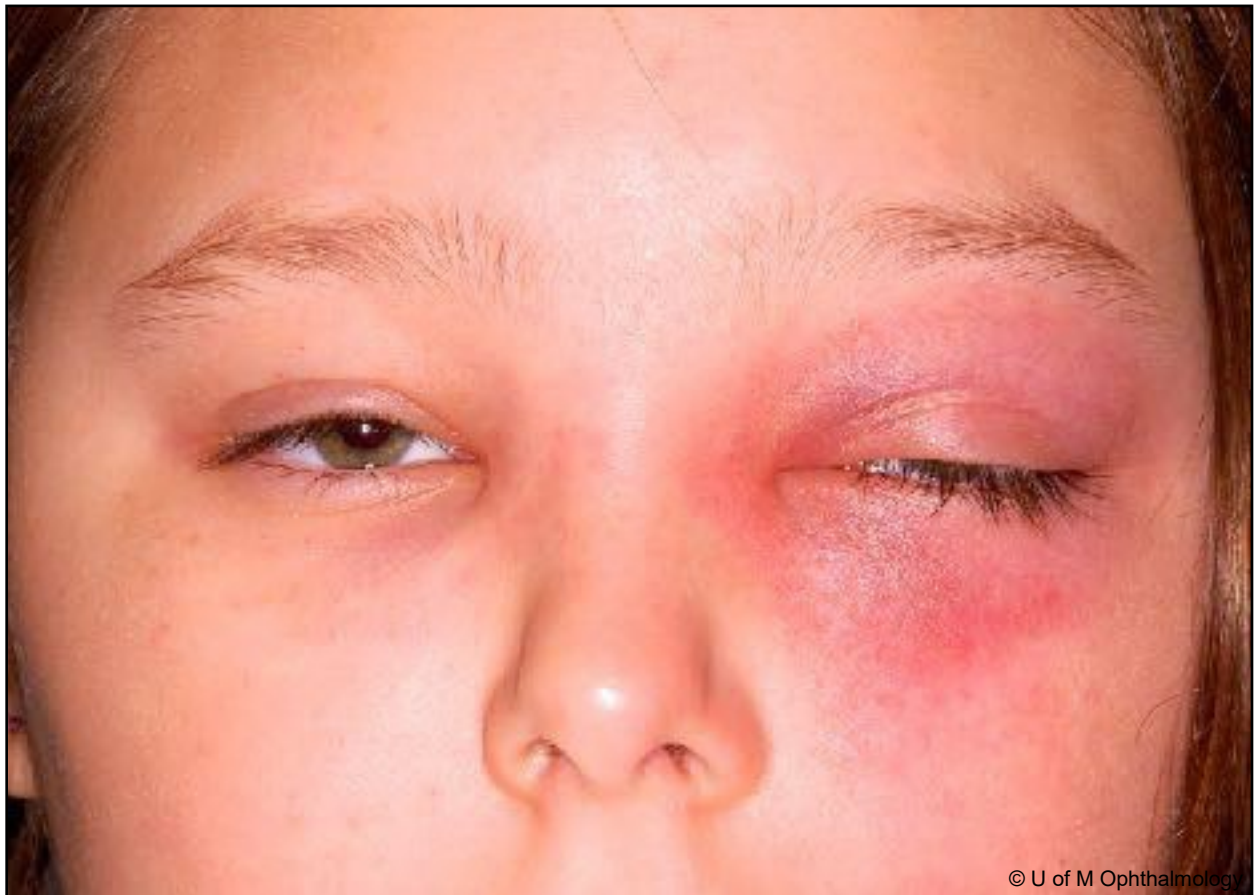This firm, non-tender swelling is a chalazion. They grow gradually and there may be a history of previous similar lesions. No treatment is needed for this, though incision and curettage under local anesthesia will hasten resolution.



© U of M Ophthalmology

This child has a resolving granulomatous inflammation caused by a chalazion. It needs no treatment. (If this were an adult, the differential diagnosis would include basal cell, and squamous cell carcinoma)

Cellulitis: it is impossible to tell from this image whether this is caused by orbital, or pre-septal cellulitis

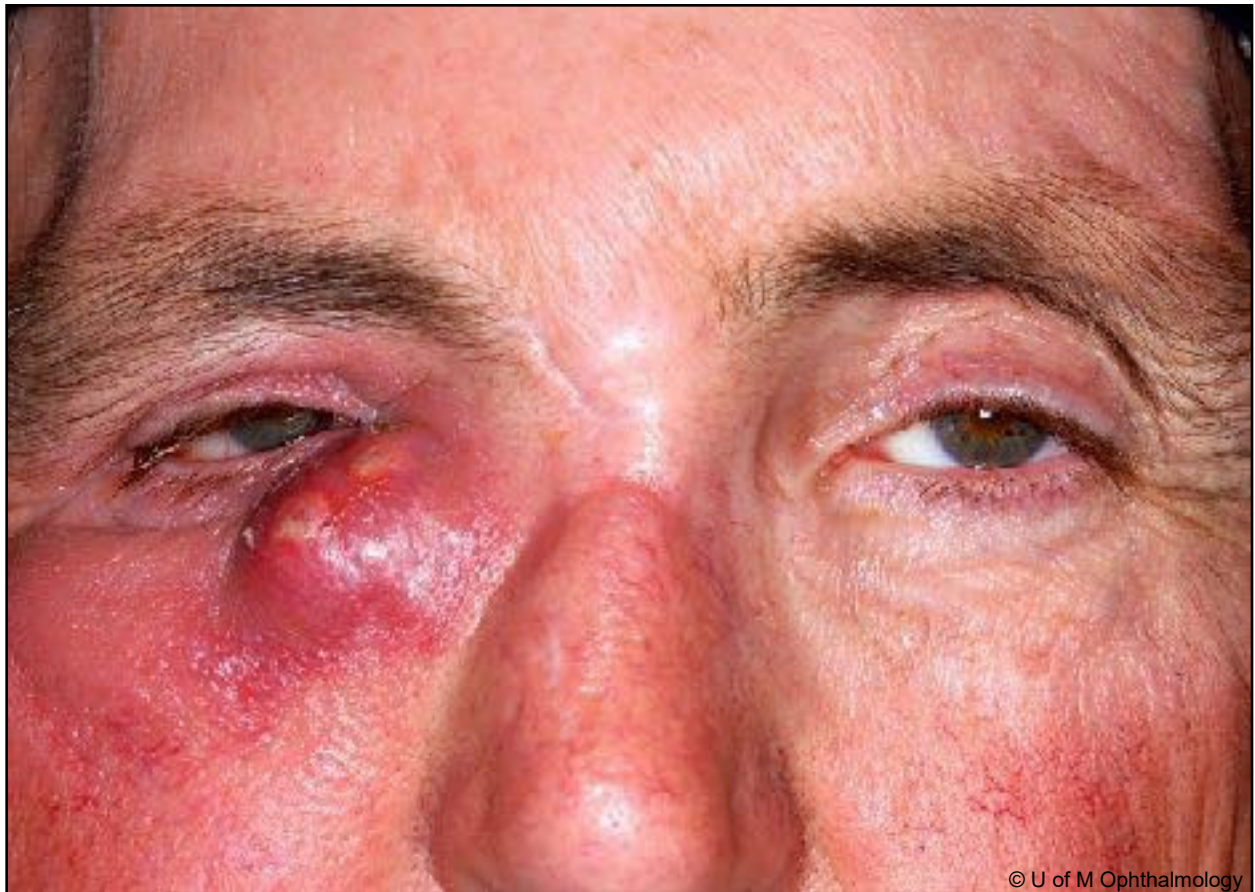

Signs that suggest a pre-septal infection include an obvious wound, or source of infection on the skin.

Orbital cellulitis causes inflammation and swelling behind the eye. This results in proptosis, and reduced eye movements as it progresses. Patients may complain of diplopia if their eyelid is not closed. As the pressure behind the eye increases it may start to affect visual function (check acuity, and check for a relative afferent pupillary defect).

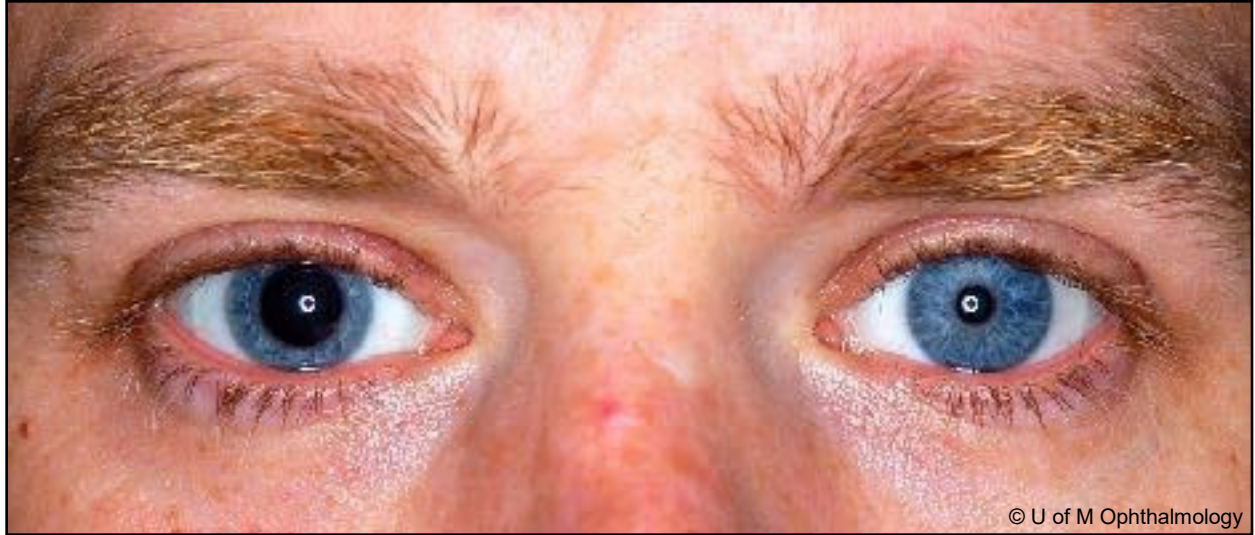

Dacryocystitis:



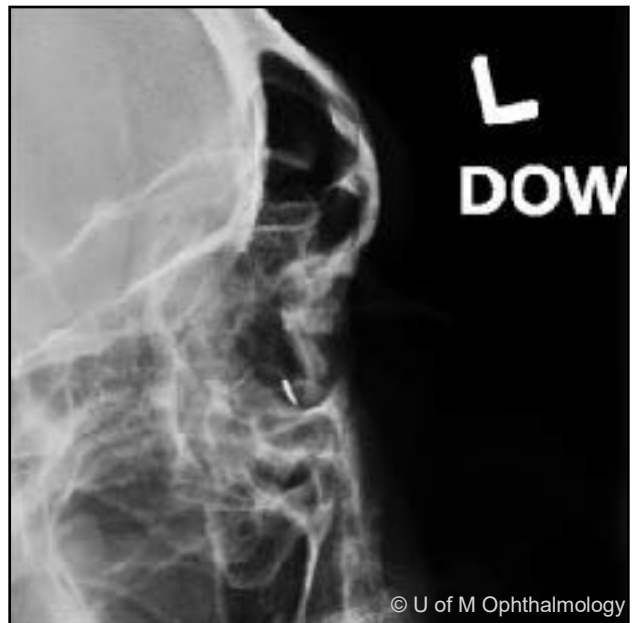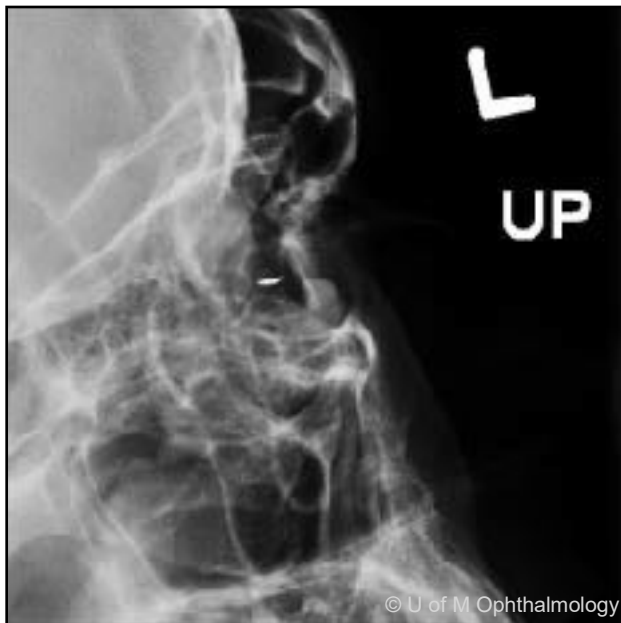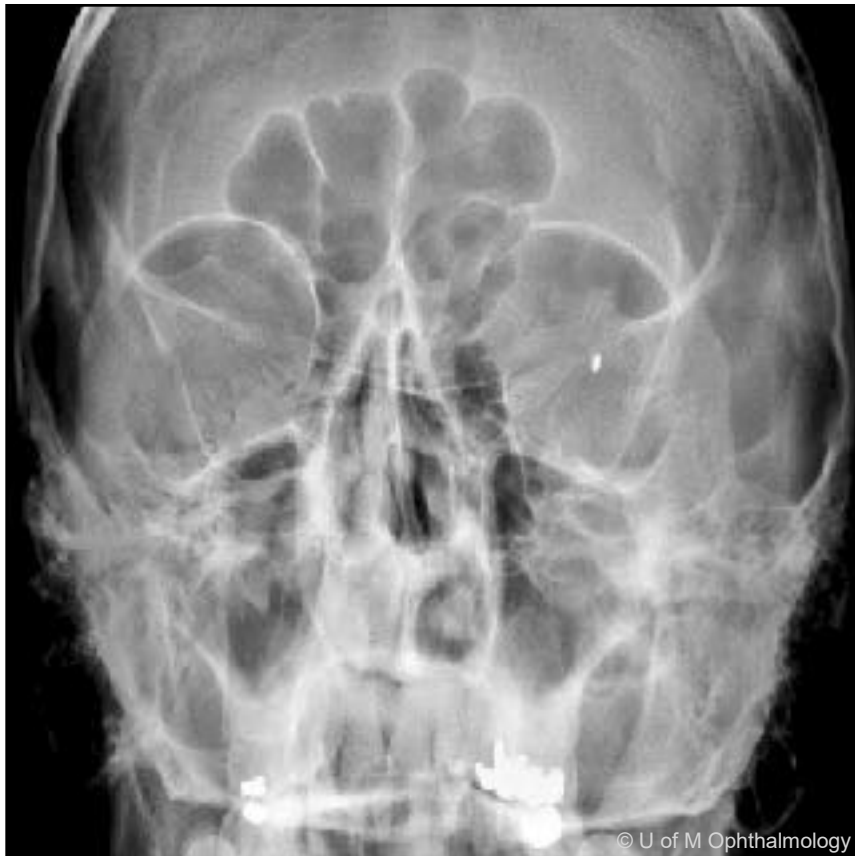There are all the signs of inflammation surrounding the abscess in this patient's nasolacrimal sac. The swelling is situated below the medial canthus.

Anisocoria after pharmacologic dilation of the right pupil:



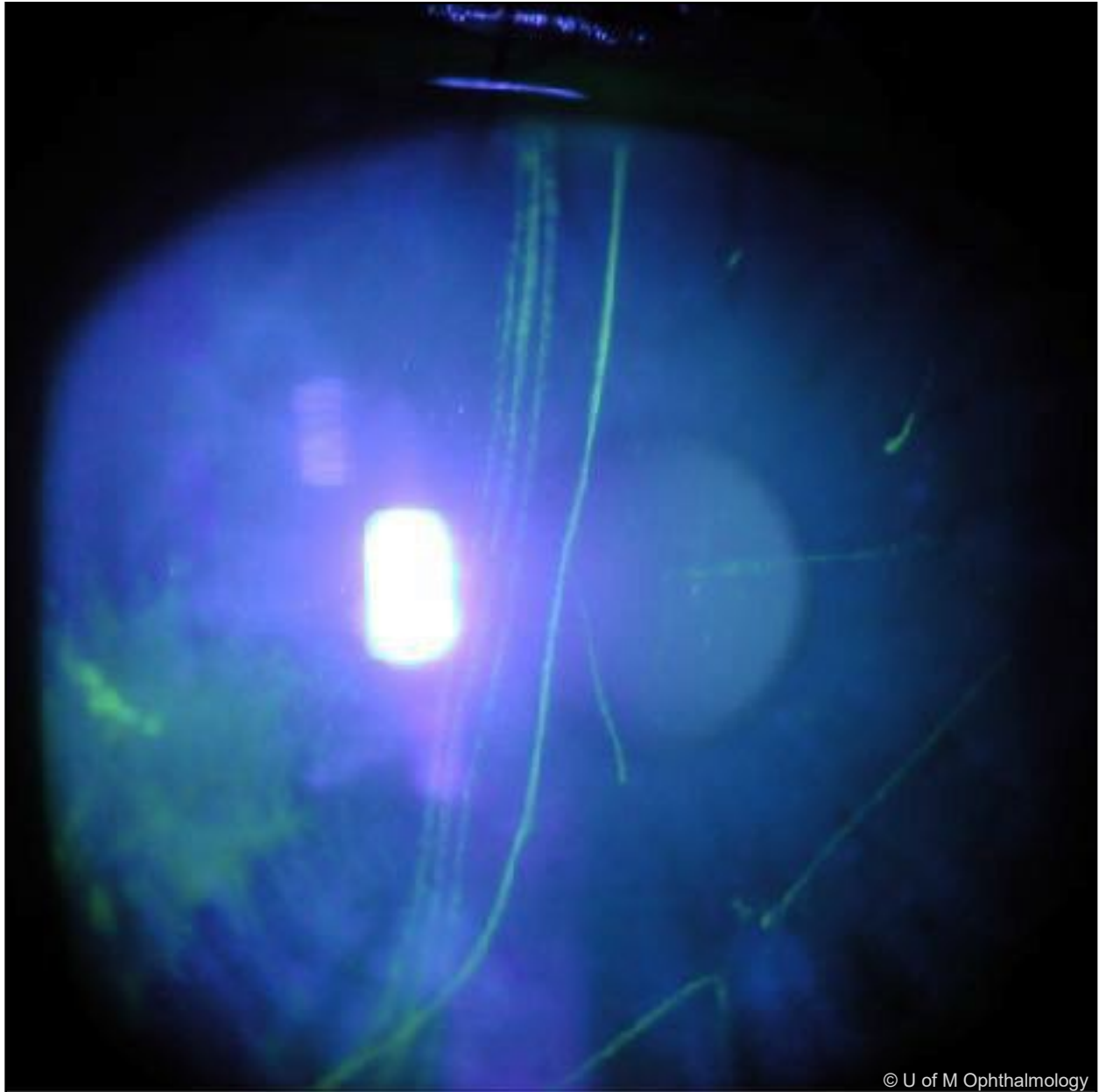
The left pupil reacts normally and the right is totally unreactive (to light or accommodation), and very dilated. The patient has no other neurological signs (no ptosis, normal eye movements...).

Intraocular foreign body in the left eye shown on these plain x-rays:



The FB can be seen to move when the patient moves their eyes, so it must be intraocular.

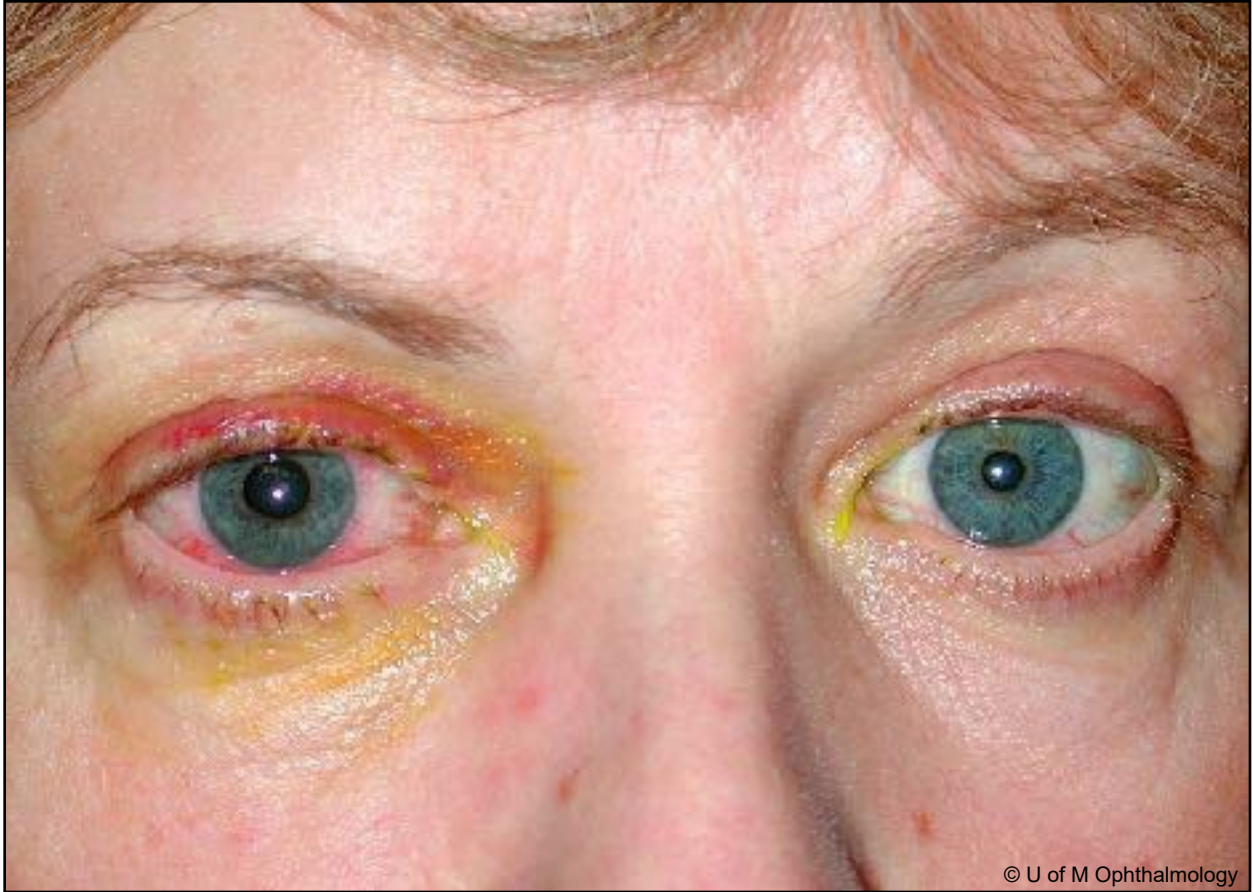Vertical linear corneal abrasions caused by a [sub-tarsal foreign body](#):



The photo shows a magnified view of the cornea only. The pupil can just be seen to the right of centre. The linear scratches, which stain with fluorescein, are caused by the FB abrading the corneal epithelium with every blink of the eyelids. Evert the upper lid to find and remove the offending FB.



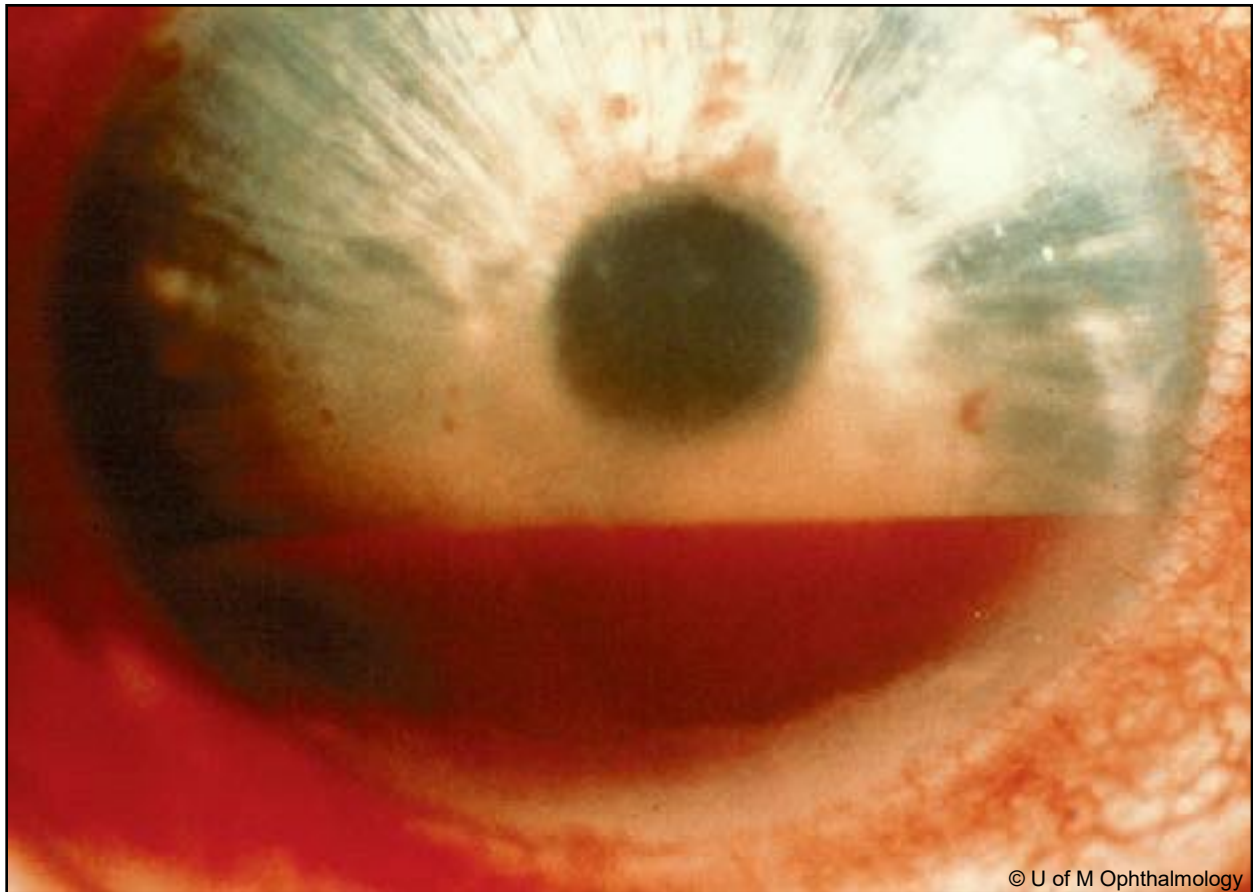Traumatic mydriasis after [blunt trauma](#):



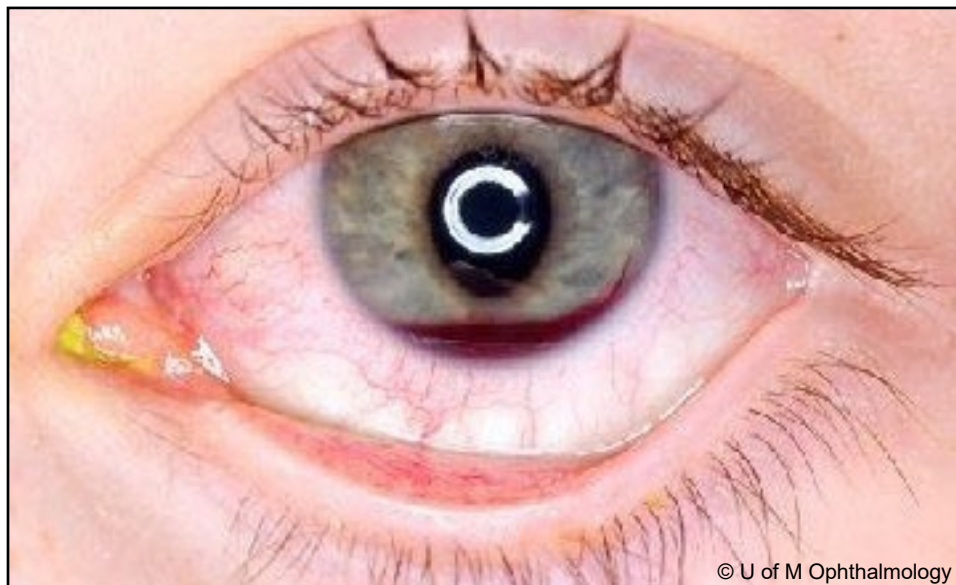
Blunt trauma to the right eye has caused an irregular dilation of that pupil along with some obvious bruising to the upper lid. The eye is a little injected due to a traumatic uveitis, which will make the eye photophobic and ache.



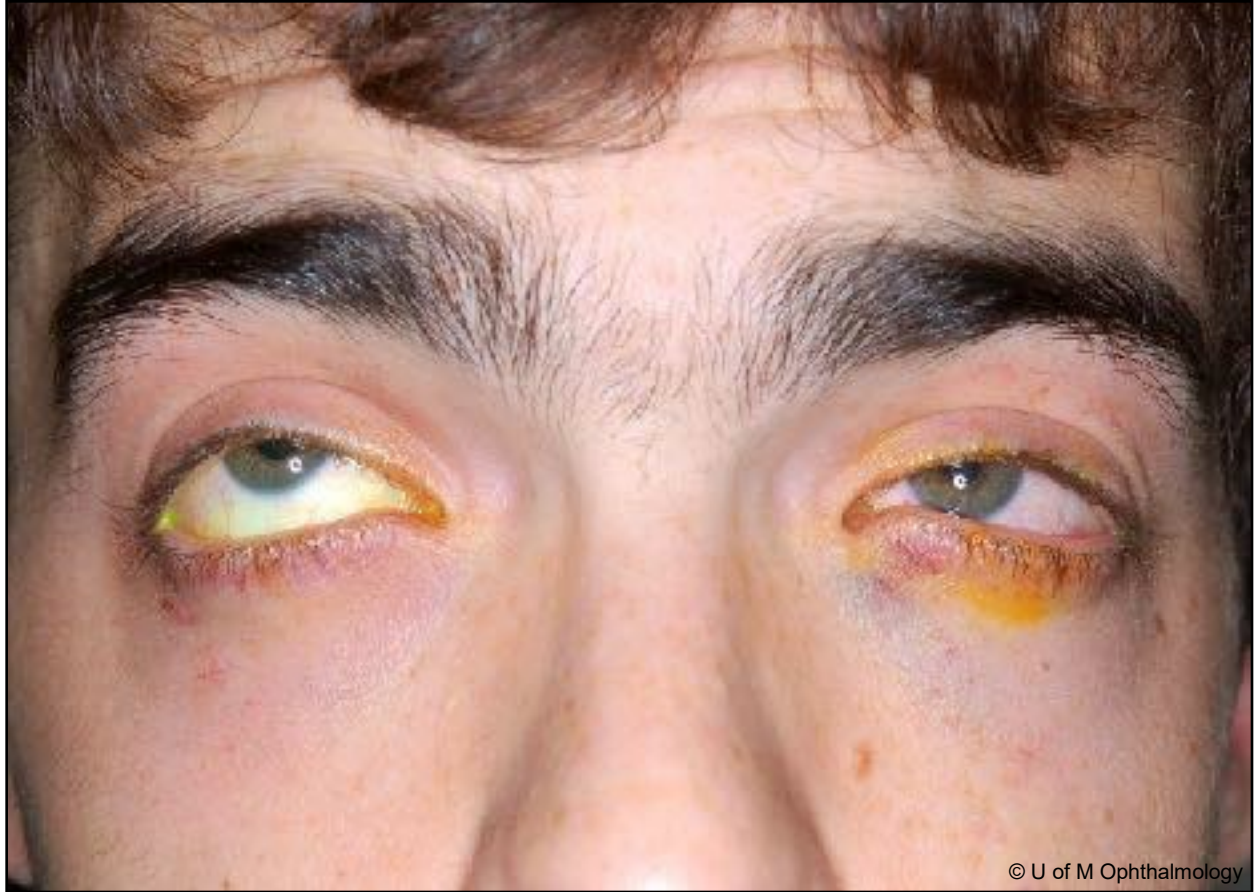Hyphema:



This is a large hyphema, but they may be smaller, as shown in the image below.



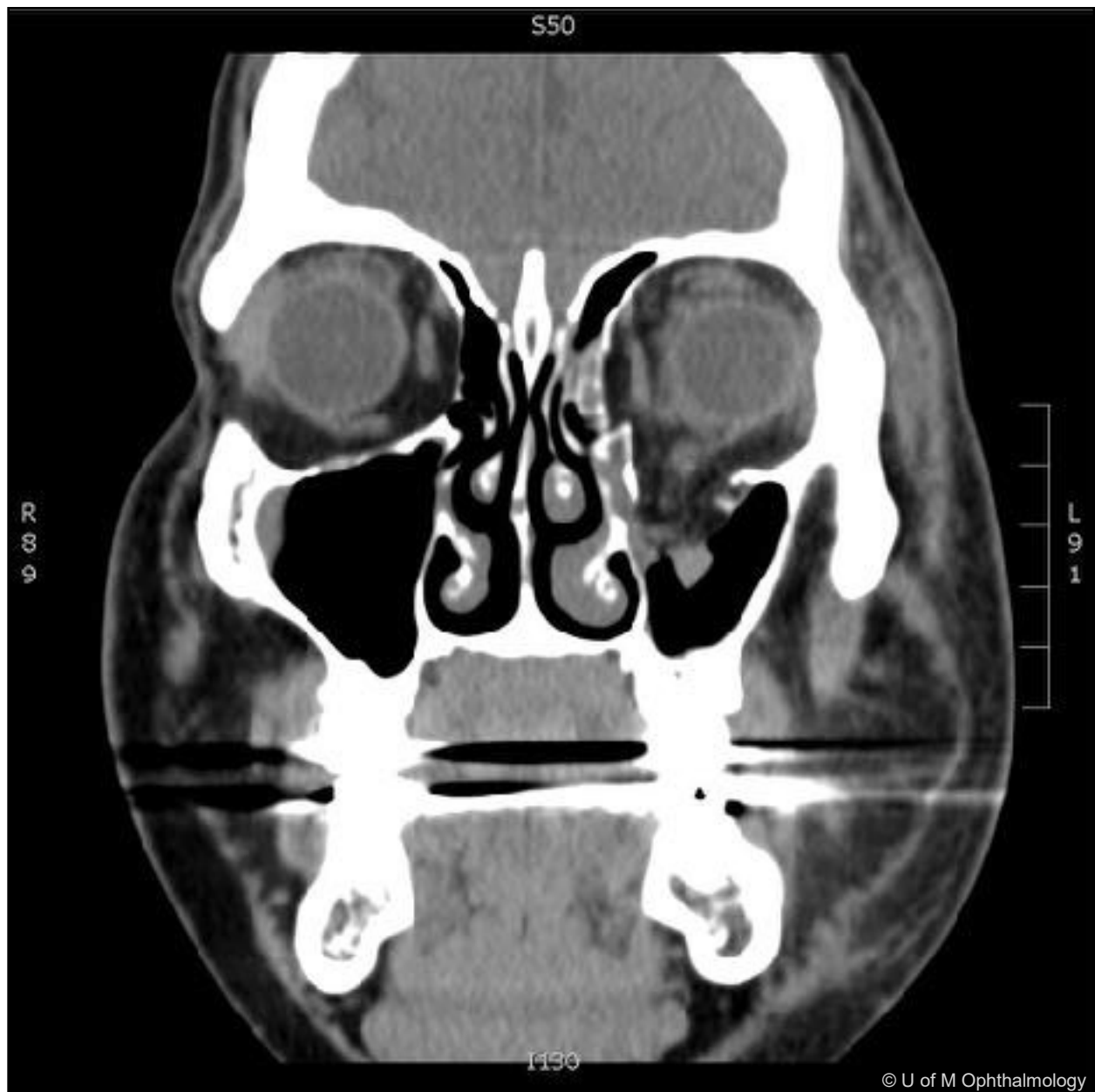Left [blow-out fracture](#) (of the orbital floor) with limited upgaze:



The left eye fails to elevate when the patient tries to look up due to entrapment of orbital tissues in the fractured orbital floor. (A similar restriction may be seen in attempted left or right gaze in patients with a medial orbital wall fracture).

See this patient's CT on the next page.

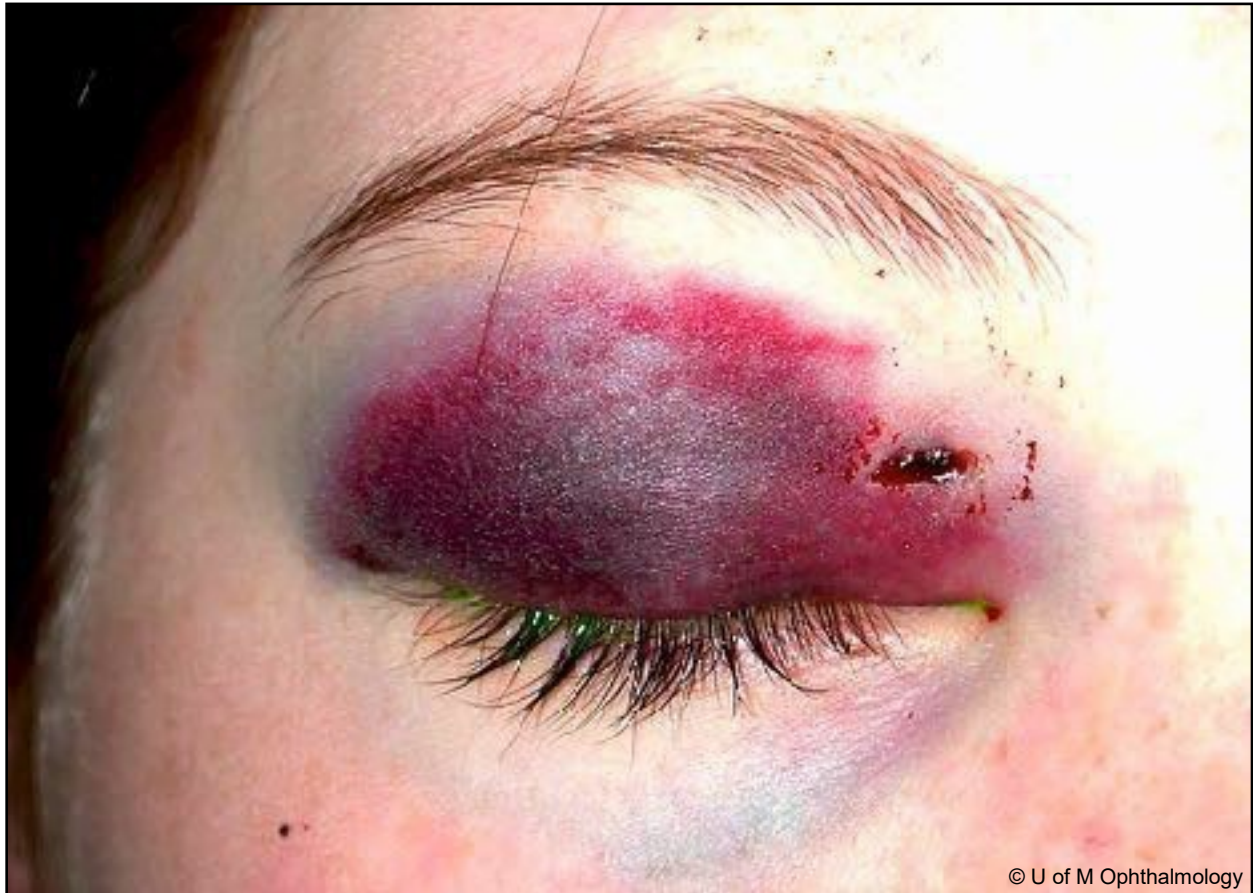Coronal CT showing an extensive left [orbital floor fracture](#):



Left orbital floor fracture with orbital tissue prolapsing into the maxillary sinus.



Apparently innocent [eyelid lacerations](#) may be associated with penetrating eye injuries or injury to other adjacent structures:

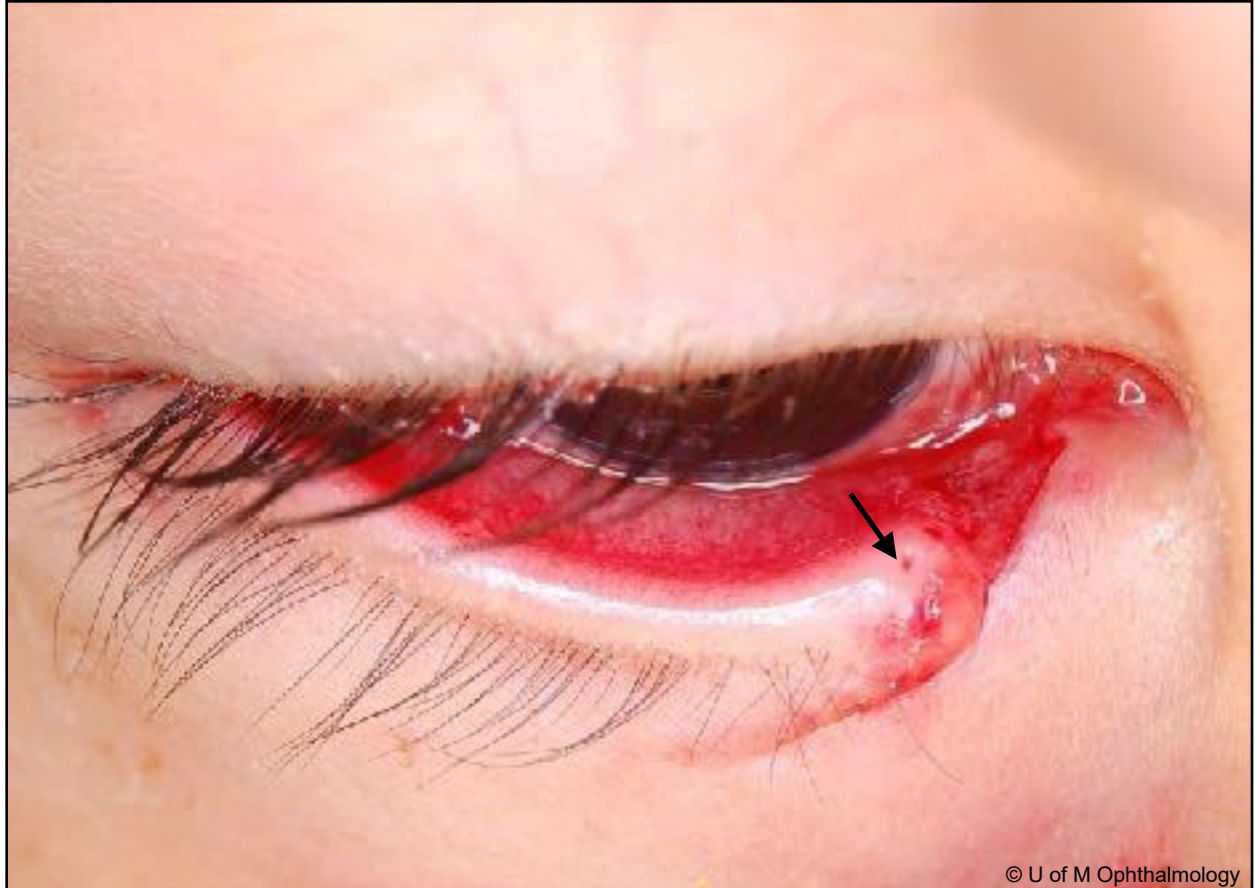

This wound was created by a twig as the child ran through a forest. There is no way of knowing how far into the orbit the twig penetrated.

It is possible that it could have

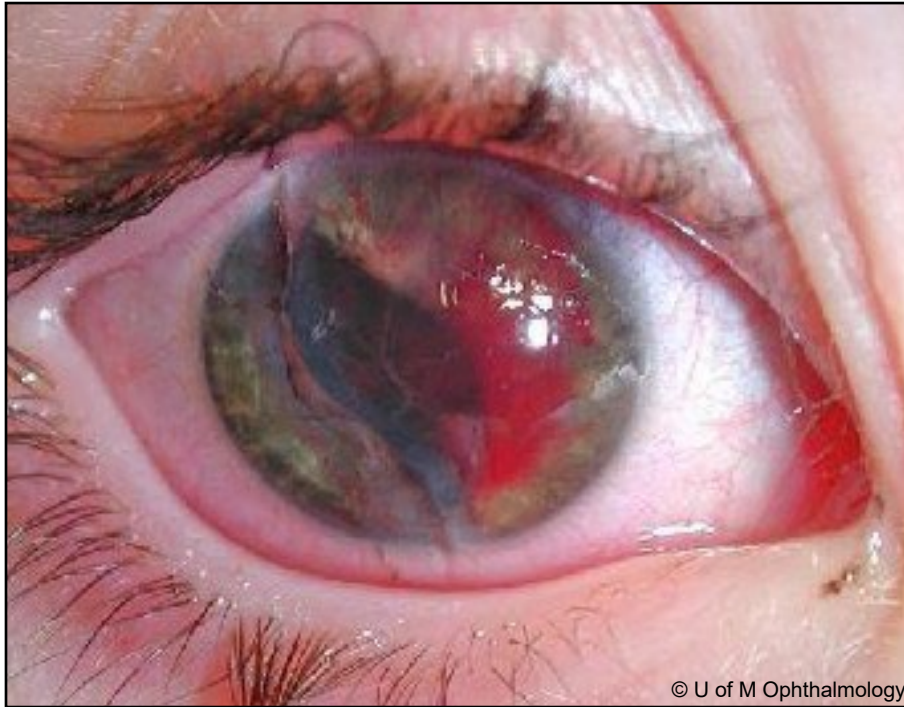- broken off leaving an intraorbital FB
- caused a penetrating eye injury (a normal visual acuity is reassuring, but does not exclude a serious injury to the globe)
- injury to the adjacent sinuses or even the frontal lobe are possible

Lid laceration involving the lacrimal system:



There is a very obvious right lower lid laceration that involves the lid margin. It is medial to the lower lacrimal punctum (marked by an arrow). This will have divided the lower lacrimal canaliculus, so the surgical repair will be more complicated (compared to lacerations situated lateral to the punctum).

### Penetrating eye injury:

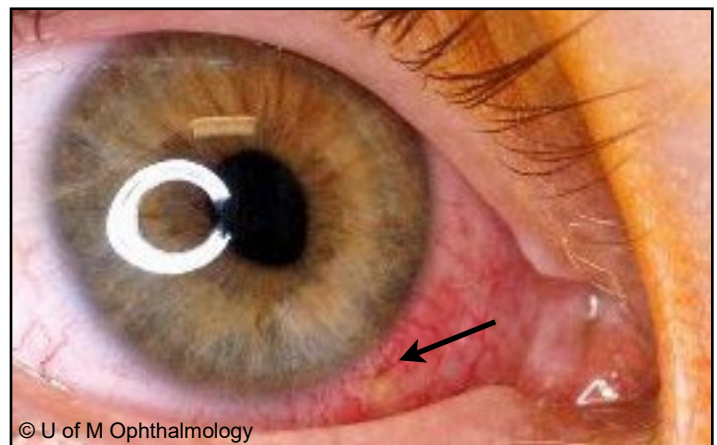


This wound was caused by a sharp object. You can see that it has caused corectopia (a distorted pupil), there is blood in the anterior chamber, and an obvious laceration spans the central cornea from the limbus at 10 o'clock to the limbus at 6 o'clock.

This child was in no pain, sitting quite comfortably in the waiting room. The sharp nature of the laceration did not result in a corneal abrasion, just a clean wound, so his discomfort was minimal.

Injuries with small sharp objects (nails and tacks...) may be harder to spot as the wounds can seal. Maintain a high index of suspicion if there is a history of an injury with a sharp object. Look out for staining with fluorescein and also look for any distortion of the iris/pupil. This can occur if a wound becomes plugged with uveal tissue.

The image to the right shows a pupil that is pulled to a small dark area, just posterior to the limbus. Fluorescein stains the same area (marked with the arrow). A nail entered the eye at this site and the uveal tissue plugged and sealed it, dragging the pupil towards the wound.

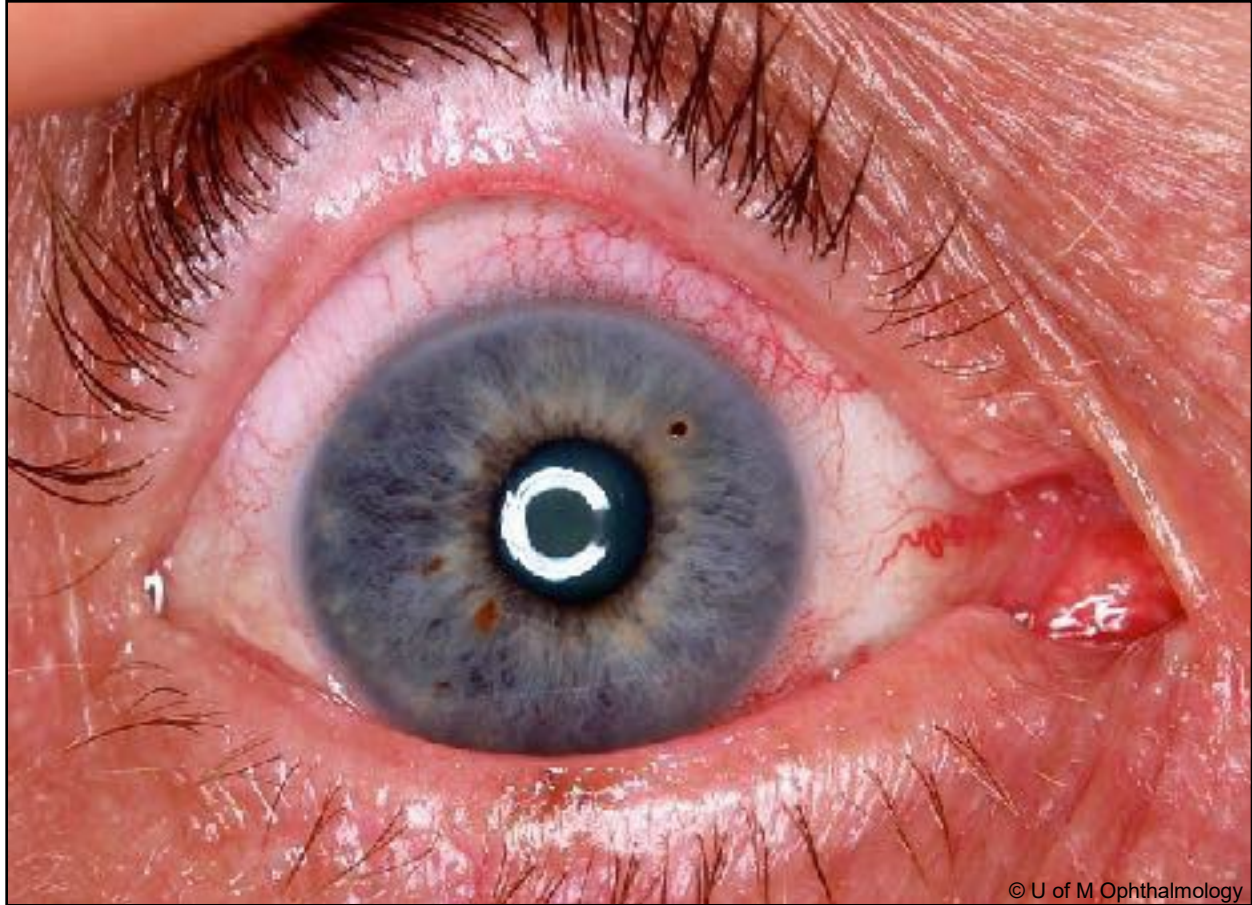


[Ophthalmia neonatorum:](#)

No good image available at this time, but there is a representative image available in [eMedicine](#).



Metallic corneal foreign body:

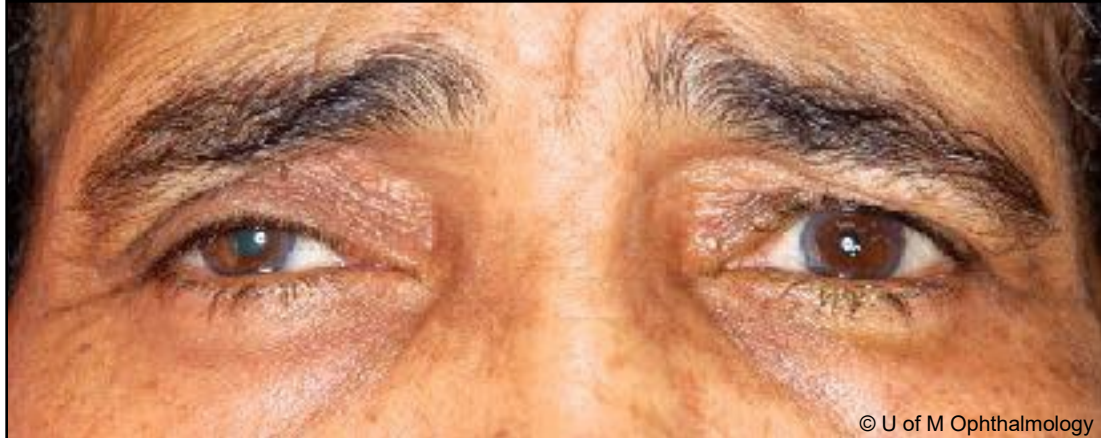

A rust-colored FB can be seen on the cornea at the 2 o'clock position. This is best removed with a 21G needle at the slit lamp to minimize trauma to the healthy corneal epithelium. Once removed, the patient can be treated like any corneal abrasion.

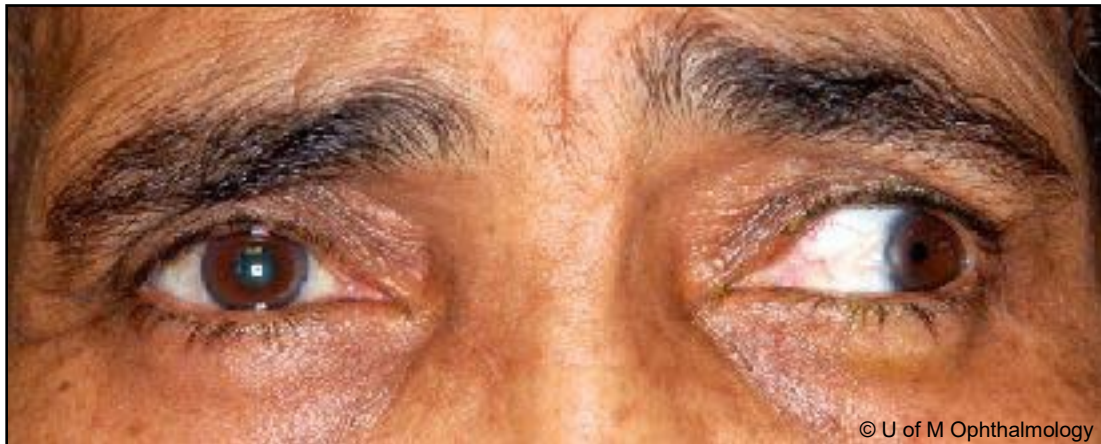Note that a history of hammering metal on metal makes a [plain x-ray of the orbits](#) mandatory (it is indefensible to miss an intraocular foreign body by failing to obtain plain films when there is a history of a metal-on-metal impact).



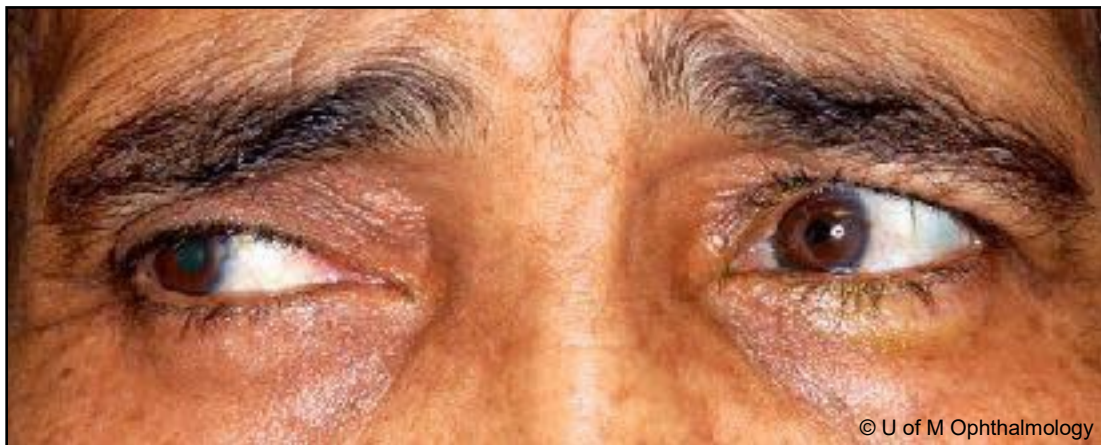Third cranial nerve paresis:



Looking straight ahead. Notesubtle exotropia, ptosis and anisocoria.



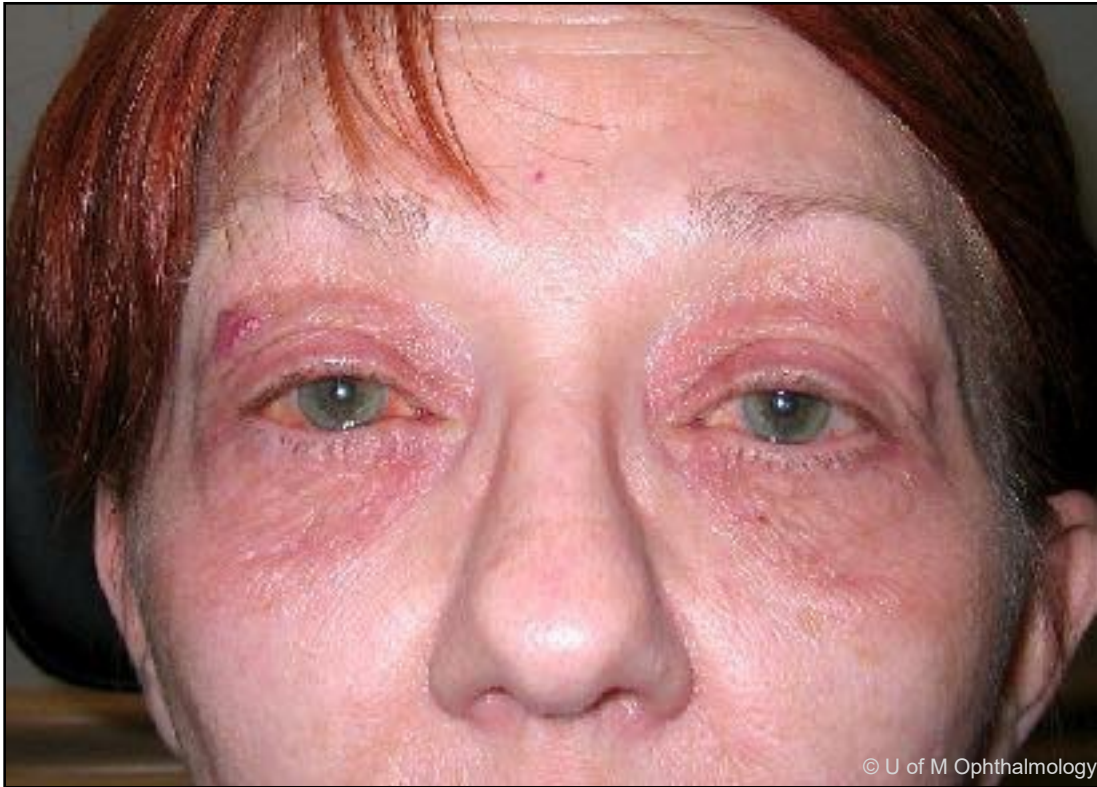Attempted left gaze



Right gaze

Right partial ptosis, enlarged pupil and total failure of adduction with normal right abduction (due to normal VI function) in a patient with a third cranial nerve paresis. This patient needs urgent neuro-imaging to exclude an intracranial aneurysm. (Upgaze and downgaze may also be impaired for the right eye).

Chronic eye drop use with hypersensitivity and dermatitis:



It is not uncommon to see a patient bring a bag containing a couple of antibiotic eyedrops, some artificial tears, a topical antihistamine, a steroid/antibiotic combination... all of which have been used in the preceding weeks to try to help with a red eye. In this setting, the drops can cause a hypersensitivity reaction, and even a dermatitis around the eye (as in the image above). You may see conjunctival follicles in the lower fornix as well.

In this situation, the best thing to do is to advise the patient to stop *everything*. A few days later the symptoms will more than likely be vastly improved and they may not even need a referral.

If their symptoms do not settle then at least the examining ophthalmologist has a sporting chance of working out the cause of their symptoms (it is very difficult to make a diagnosis when patients have a hypersensitivity reaction, as the signs associated with the underlying cause are often masked).