Common Skin Disease

Surangkana Veeranawin, MD

MSc, Queen Mary University of London

Mmed, University of Sydney

DipDerm RCPS(Glas.)

Diplomate American Broad of Aesthetic Medicine (ABAM)

Acne Vulgaris

- Inflammatory disorder of pilosebaceous follicle with a 90% prevalence in adolescence and young adulthood.
- **History**: often asymptomatic lesions (especially comedone), although can be tender (nodules)
- **Physical:** two types of lesions, predominantly affect face, neck, chest and back

- Noninflammatory; open(“black head”) and closed (“white head”) comedones

- Inflammatory; papules, pustule, cysts, nodule: deep lesions (leave scars)

Acne Vulgaris

- 4 Major components
  - Abnormal follicular keratinization: follicular wall cells fail to desquamate to the surface in the normal manner.
  - Sebum over production secondary to androgen
  - *Propionibacterium acnes* infection; they grow in the sebum-cell mixture.
  - Inflammation

- Other components; genetic factors, occlusive cosmetic agents, medication (steroids, ACTH, androgens, lithium, antiepileptics, oral contraceptives), diseases (PCOS, Congenital Adrenal Hyperplasia)

Acne

Treatment Strategies

- Retinoid for clearing pores and comedones for all acne conditions

- ***Small inflammatory lesions*** → Topical Benzoyl Peroxide (BP) & Topical Antibiotic

- ***Large inflammatory lesions*** → Oral antibiotic

Acne

<u>Mild</u> ➔➔ Topical Only

- ***Decrease follicular plugging***
  - Retinoid
    - Nightly
    - Adapalene (Differin); if can not tolerate retinoid
  - Salycilic acid wash/scrub

- ***Decrease P. Acne***
  - Topical Antibiotic
    - Clindamycin
  - Benzoyl peroxide; bacterialcidal, decrease sebum/oil

Acne

<u>Moderate</u> or nonresponsive to topical

- Add oral antibiotic
  - Tetracycline

    250 – 500 mg twice/day
  - Minocycline

    50 – 100 mg twice/day
  - Doxycycline

    50 – 100 mg twice/day

- ***Add chemical peel*** → Salicylic or Jessner

Acne

- Other treatment

  - comedone extraction, intralesional cortisone injection (for papulonodules, cysts), oral contraceptives (esp. anti-androgenic such as cyproterone acetate), photodynamic therapy, spironolactone (reduces androgen production; 50 – 200 mg/day), dermabrasion

  - Patients should be forewarned of acne exacerbations in the first month of systemic therapy as deep-seated acne comes to the surface. Also, systemic therapy can required 6 wk before benefits are noted

Rosacea

- Chronic vascular & acneiform disorder
- Common chronic inflammatory disorder of pilosebaceous units and vasculature of the face
- Role of *Demodex* mite controversial
- Increase reactivity of capillaries ➔➔➔Flushing➔➔➔ultimately leading to telangiectasia

Rosacea

- Easy and recurrent flushing
- Sensitive skin
- More common in fair skin
- May complain of dry and gritty eyes
- Female > male
- Peak incidence 30-50 yr

Rosacea

EXACEBATE BY

- Heat,rapid change in temperature
- Sun exposure
- Cold
- EtOh
- Stress
- Spicy food
- Hot food/beverage
- Caffeine

- Clinical appearance: Erythema, telangiectases, papules, and pustules of central face; no comedones in contrast to acne.
- Erythema of the nose is highly characteristic of rosacea
- Accompany with, sebaceous hyperplasia, seborrheic dermatits & facial lymphedema more common

Rosacea

- Predominantly central face

  - Forehead

  - Cheeks

  - Nose

  - Chin

  - Occasionally eyelids

Rosacea

- **4 Major subtypes**
  - ***Vascular rosacea (Erythematotelangiectatic rosacea)***
  - ***Papulopustular rosacea***
  - ***Ocular rosacea:*** *gritty, conjunctival injection, styes and photophobia. (The eye is involved in about 50% of cases)*
  - ***Nasal sebaceous hyperplasia*** (rhinophyma): chronic inflammation may progress to rhinophyma (more common in male)

ROSACEA

ROSACEA

RHINOPHYMA

PAPULOPUSTULAR

Rosacea

- Investigation

  - Clinical diagnosis

  - Skin biopsy to rule out lupus or sacoidosis

- Differential Diagnosis

  - Acne - Lupus erythematosus - Sarcoidosis

  - Seborrheic dermatitis - Perioral dermatitis

Rosacea

- **Management**

  - Based on severity and subtype.

  - Lifestyle modification : Avoid triggers ; sun protection & avoidance.

  - Topical antibiotic

    - Metronidazole 0.75% gel or 1% cream bid
    - Sodium sulfacetamide lotion 10% bid
    - Azelaic acid QD

Rosacea

- Oral antibiotic (moderate to severe cases with inflammatory papulopaustular component)

  - Tetracycline 500 mg po BID
  - Minocycline 100 mg OD – BID
  - Doxycyline 20 mg po bid (subantimicrobial dose therapy) or 100 mg po qd-bid

- Isotretinoin and prednisolone for very severe cases

Rosacea

- Light therapy
  - ***Treatment of Choice*** → IPL (400nm – 1200nm), PDL (595 nm) for telangiectases
  - Ablative laser (CO_2) for rhinophyma

- Ophthalmologist to assess for ocular involvement (blepharitis, conjunctivitis)

Pityriasis rosea

- Acute, self-limited papulosquamous inflammatory skin exanthem in 15-40 yr.
- The primary lesion is an oval, salmon-colored, 1-10 cm plaque that forms a round collarette of scale in the center.
- It evolves rapidly, usually beginning with patch that heralds the eruption, the so-called “herald patch.
- Clinical appearance: Scaly pink-erythematous plaques; predominantly trunk affected, in “Christmas-tree” pattern

Pityriasis rosea

- Etiology: Possibly triggered by human herpes virus 7
- History: May be pruritic or asymptomatic; preceding URTI or mild constitutional symptoms
- Lesions are found on the trunk and usually spare the face and extremities
- The number of lesions is highly variable. Plaques may extend to the neck and proximal limbs
- Numerous lesions may appear. A concentration of lesions on the groin and lower abdomen is highly characteristic, especially in children

Pityriasis rosea

Pityriasis rosea

- Course: Self-resolving in 6-8 weeks
- Investigations: Clinical; scraping for KOH (R/O tinea) or order RPR (R/O syphilis), or skin biopsy if uncertain.
- DDx: Eczema, psoriasis, tinea corporis, syphilis, seborrheic dermatitis

Pityriasis rosea

- Management

  - Reassurance is key

  - Symptomatic management of pruritus (e.g. mild topical steroids, antihistamines); mentholated lotion or sprays for itching

  - Erythromycin 250 mg, q.i.d or 25-40 mg/kg in four divided doses in children for 2 weeks may clear the eruption

  - Light therapy (e.g. UVB) may help hasten resolution and relieve pruritus

Lichen Planus

- Acute or chronic inflammatory disorder affecting the skin, scalp hair follicles, mucous membranes, and nails (5%-10%)
- Etiology: Likely an immunologically mediated reaction; oral erosive lichen planus associated with hepatitis C (Characteristic eruption of unknown etiology)
- History: Uncommon in children. Family history is 10%. Pruritus common; oral lesions may or may not be symptomatic. Ask about Hep C risk factors (e.g., transfusions) for oral erosive LP. May be drug-induced.

Lichen Planus

- Physical: **7 P's**

- Planar (flat-topped)
- Pruritic (intense)
- Purple
- Polygonal
- Papules
- Penile (commonly affected)
- Prolonged course (up to 18 mo; longer in some case)

- Distributed on flexor surfaces, penis (glans), mouth (lacy white patches or erosions – Wickham striae)
- *Koebner phenomenon:* appearance of lesions at sites of trauma

Lichen Planus

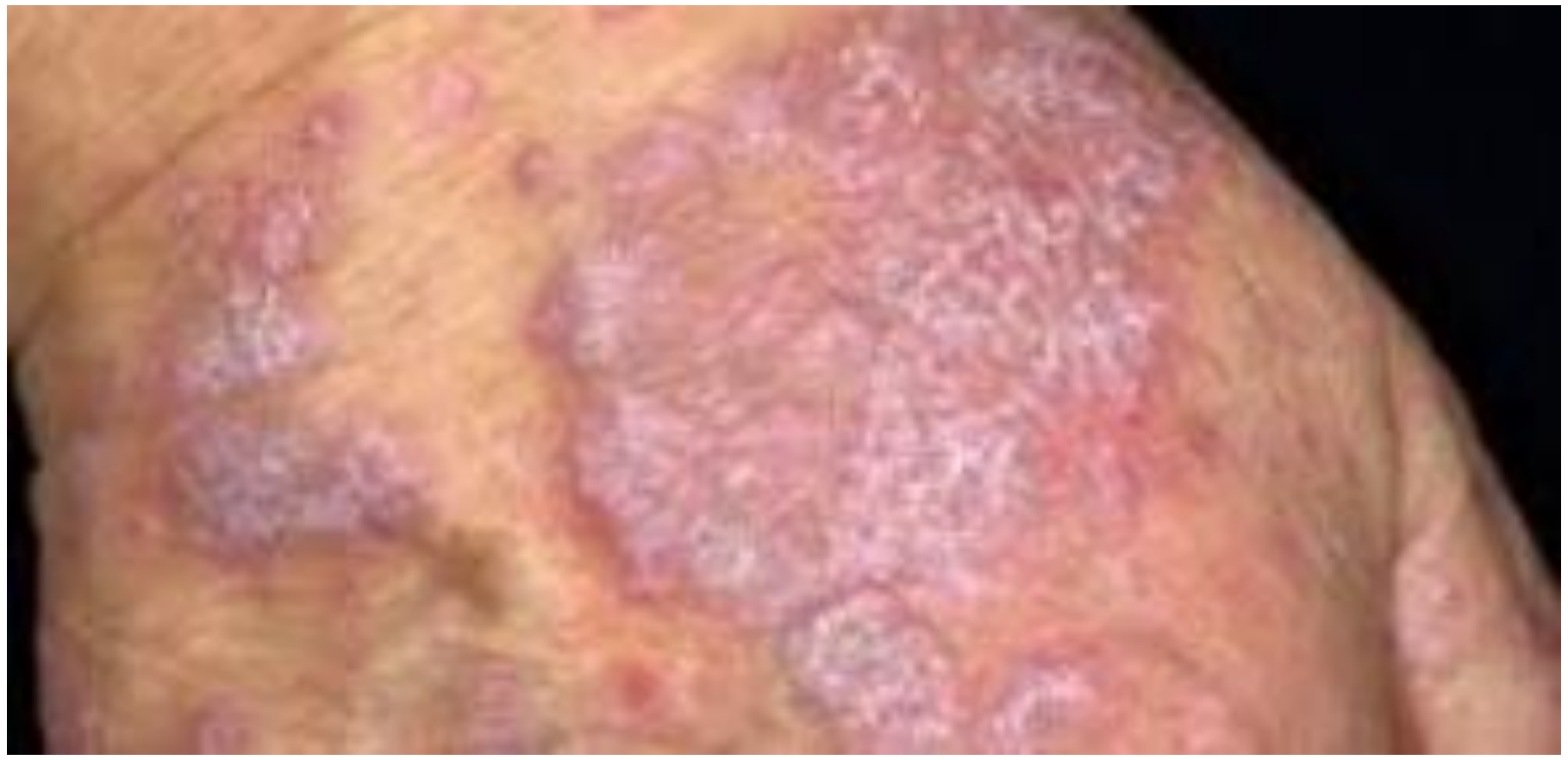

Lichen Planus

- Course: May resolve spontaneously or have chronic course (esp. oral LP); increase risk of oral SCC in oral LP
- DDx: Drug reaction, Pityriasis rosea, Psoriasis
- Investigations: Skin biopsy if unsure of diagnosis

Lichen Planus

- Management
- Topical: Mild to high potency steroid bid for 2 weeks; intralesional if hypertrophic/thick. Triamcinolone acetonide in adhesive base for oral lesion
- Systemic: (if severe and generalized)
  - Prednisolone; a 4 weeks course starting at 1 mg/kg q.d.
  - Retinoids
  - UV therapy
  - Cyclosporine
  - Metronidazole 500 mg po bid * 6 wk, sedative antihistamines for itching

Psoriasis

- Common (1%-2% prevalence), chronic, recurrent inflammatory skin disease with unpredictable course.
- Onset: any age, peaks late twenties
- Etiology: Genetic & environment factors; abnormal epidermal differentiation and hyperproliferation initiated and maintained primarily by T-cell
- History: Visible itchy red plaques with increase skin scaling and peeling. May have joint pain (7-20%). May have preceding URTI (*Streptococcus infection)*. Worsened by smoking, alcohol & stress, physical trauma

Psoriasis

- Physical: Most common chronic plaque psoriasis. Characteristic sharply defined, erythematous plaques with silvery-white scale; distributed over extensor surfaces (elbows, knees), scalp, sacrum and other sites

- Nail psoriasis: Pitting, thickening, “oil-drop”, lifting of nail plate off of distal nail bed (onycholysis)

- Koebnerization = new lesions occur at sites of skin trauma (as with lichen planus)

Psoriasis

- Variants: Vulgaris, palmoplantar, guttate (may follow streptococcal pharyngitis), erythrodermic, pustular, inverse (affects folds and flexor surfaces)
- Drug may precipitate or exacerbate psoriasis: Antimalarials, clonidine, indomethacin, iodine, lithium, NSAIDS, quinidine, some beta-blockers, steoids withdrawal and terfenadine.

Psoriasis (Plaques type)




Psoriasis (Erythroderma)

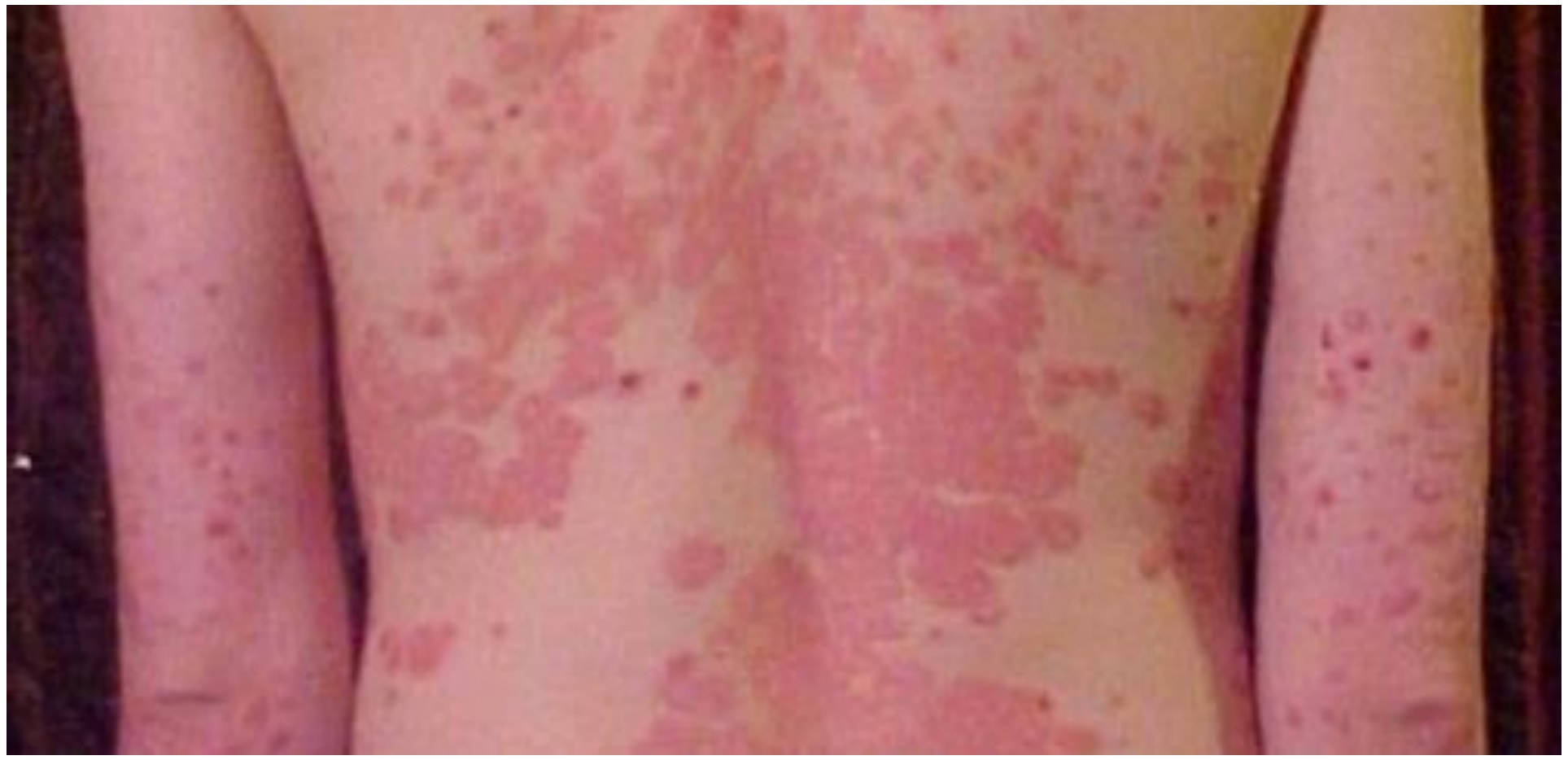

Psoriasis (Guttate type)

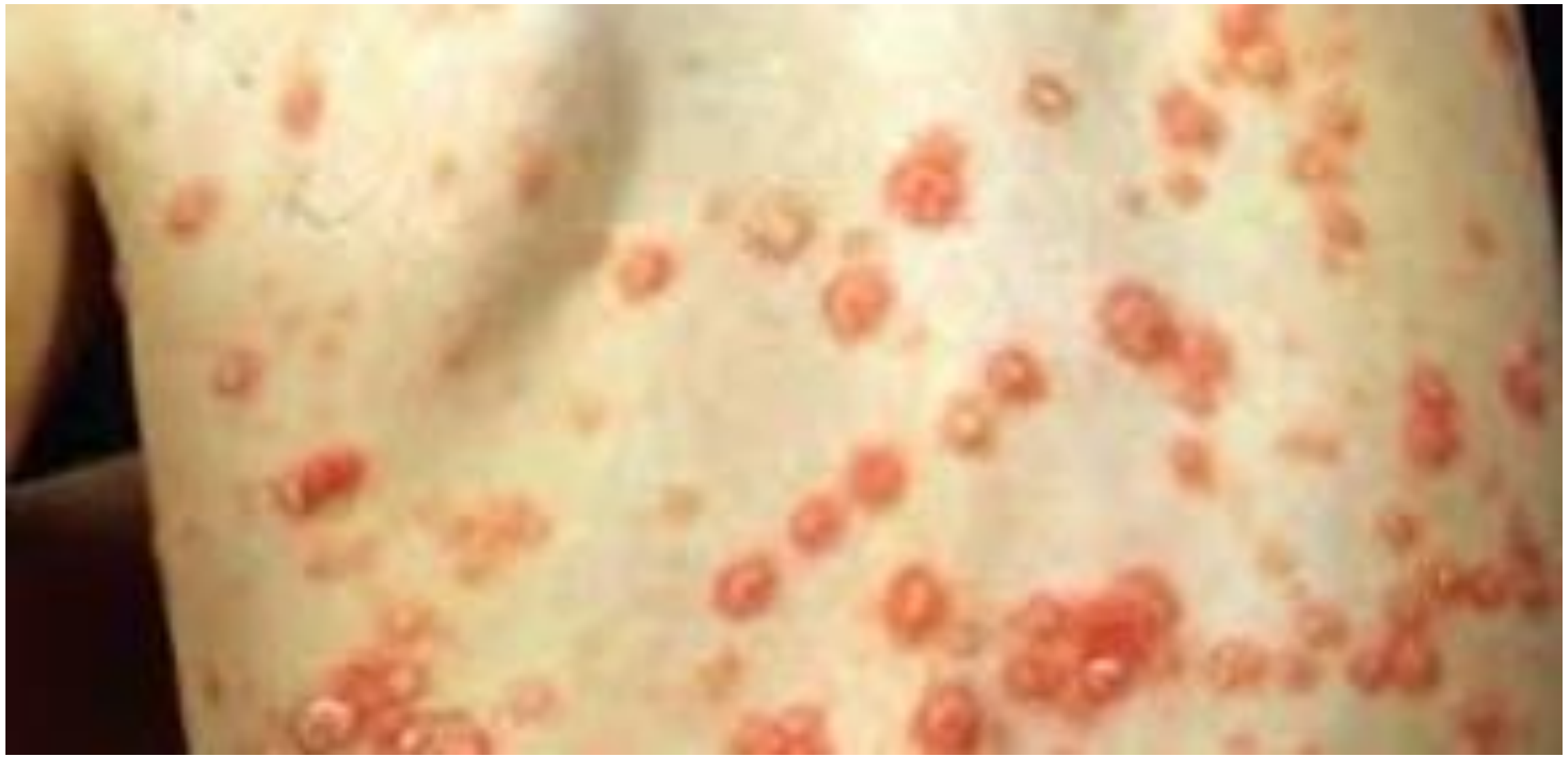

Psoriasis (Palmoplantar)

Psoriasis (Inverse type)

Psoriasis

- In 10-20% may be associated with *psoriatic arthritis,* most commonly of the small joints of the hands and feet; requires systemic Tx
- Investigation: Clinical diagnosis; skin biopsy if uncertain
- DDx: Drug reaction, eczema. Lichen planus, pityriasis rubra pilaris

Psoriasis

- Topical

- Steroids; Fast, temporary relief (atrophy, telangiectasia)

- Calcipotriol ointment, 100g bid. on weekdays as tolerated + topical steroid bid., weekends
- Tazarotene 0.05%, 0.1% cream qhs
- Tar preparations; low cost, effective (limited by odor, irritation, clothing stains)

Psoriasis

- Systemic

- Methotrexate; Folic acid antagonist that inhibits DNA synthesis & causes immunosuppression (Bone marrow and hepatic toxicity, nausea, anorexia, fatique, oral ulceration)

- Cyclosporine; Immunosuppressant that inhibits IL-2 production & thus reduces T-cell proliferation (Renal toxicity, hypertension)

- Acitretin; Inhibits cell replication by modulating cellular differentiation within the epidermis. May combine with PUVA or UVB.

Psoriasis

- Phototherapy

- UVB (narrowband ultraviolet B); administer 2-5 times per week.

or

- PUVA; Interferes (Psoralen plus ultravioletA) with DNA synthesis, decreases cellular proliferation, and induces apoptosis of cutaneous lymphocytes leading to localized immunosuppression. Administer 3 times per week until clear, then tapered. (Skin cancer development, photoaging)

Psoriasis

- Newer Biological Agents

- Alefacept ; Fusion protein of Fc receptor of human IgG1 and LFA3. (IM; when effective long remissions; monitoring of CD4 q wk; slow onset)

- Efalizumab ; Humanized monoclonal antibody to CD11 a; blocks LFA-1/ ICAM interaction. (SC; rapidly effective, but rebound; risk of thrombocytopenia)

- Etanercept ; Fusion protein directed against soluble TNFa(SC; effective for psoriasis & psoriatic arthritis; rapid onset; no monitoring; use +/- MTX)

- Infliximab ; Chimeric monoclonal antibody against TNFa (IV; Fast onset and very effective; must do PPD; infusion reactions.

- Adalimumab ; Fully humanized anti-TNF monoclonal antibody (SC; newest of the biologics, still being studied.

Note TNF drugs avoid or use with caution in presence of CHF, demyelination disorders. Increased risk of opportunistic infections.

Psoriasis

- Scalp; 10% salicylic acid in mineral oil qhs, tar shampoo qd, steroid lotion, calcipotriol lotion.
- Nails; Intradermal triamcinolone acetonide injections (painful), methotrexate, new biologics.
- Generalized psoriasis (>10% BSA) benefits from systemic therapy, best administered by an experienced physician

Vitiligo

- Acquired skin disorder characterized by well-defined areas of complete epidermal depigmentation; various pathogenesis theories; likely a large autoimmune component
- History; Asymptomatic: 50% present before age 20, 1-2% affected, rare in infancy & old age
- Associated with immune disorder; therefore workup for thyroid disease, diabetes, pernicious anemia and other autoimmune diseases occasionally indicated

Vitiligo

- Physical: Stark white patch with well-demarcated border; hair in vitiligo patches appears white or gray
- Increased risk of sunburn and skin cancer in amelanotic areas
- Investigations; Wood's lamp accentuates areas of vitiligo & helps determine extent; consider TSH and fasting blood glucose
- DDx; Leprosy, pityriasis alba, tinea vesicolor, tuberous sclerosis, nevus depigmentosus

Vitiligo

Vitiligo

- Management
- Mainly for cosmetic, psychological burden
- Topical steroids and new topical immunomodulators (tacrolimus & pimecrolimus), PUVA, NB-UVB, phototherapy
- Camouflage makeup
- Note that facial and more proximal lesions respond better than acral lesions
- Surgical transplants can be considered in stable vitiligo
- If extensive, can consider bleaching of nonaffected areas to result in total white color
- -Advise; importance of sun protection

Molluscum Contagiosum

- Etiology: Self-limited viral infection of skin caused by poxvirus affecting mainly children.
- Immunocompromised patients (e.g., HIV) may develop more widespread and larger lesions
- History: Asymptomatic; occasional perilesional pruritus, very common in children. Spread by direct contact or autoinoculation. Lesions tend to be more numerous and spread rapidly in patients with atopic dermatits.

Molluscum Contagiosum

- Physical: 2- to 6- mm firm, flesh colored, dome-shaped, umbilicated pearly papules; most common affected sites – trunk and face of children, genital/inner thigh of sexually active adults
- Molluscum papules in a child in the periorbital region. Lesions can be spread by picking and scratching. Lesions will be resolve with development of cellular immunity.
- Course: lesions typically involute spontaneously within 9-12 mo; may develop adjacent eczema (10%)
- Investigation: clinical diagnosis, biopsy if uncertain
- DDx: BCC, milia, other infection, warts

Molluscum Contagiosum

- Management
- Observation
- Liquid Nitrogen Cryotherapy
- Curettage: may be uncomfortable
- Papule incision with a scalpel blades or at home sharp fingernail and expression of contents
- Topical cantharidin 0.7%: Blistering will occur
- Imiquimod cream, Tretinoin cream
- In children with widespread involvement, may consider oral cimetidine (40 mg/kg/d) for 2 mo.

Molluscum Contagiosum

Pityriasis Versicolor (Tinea Versicolor)

- Etiology : Common superficial cutaneous fungal infection caused by *Malassezia furfur (Pityrosporum orbiculare),* The organism is part of normal skin
- History : May itch but usually asymptomatic, young adults typically affected (years of higher sebaceous activity) ; commonly recurs (40-60%) ; more common in hot and humid environments.
- Cushing disease, pregnancy, mulnutrition, corticosteroid therapy, immunosuppression, oral contraceptives may lower resistance, allowing this normally non-pathogenic resident yeast to poliferate

Pityriasis Versicolor (Tinea Versicolor)

- Physical : Round to oval macules and patches on the trunk extending to the upper arms, neck, abdomen; different colors: White, orange-brown, dark-brown; very fine scale; postinflammatory hypopigmentation is often noted rather than initial erythema.
- Investigations: KOH test reveals diagnostic “spaghetti & meatballs” (hyphae & spores); Wood’s lamp shows yellow-brown fluorescence. Skin biopsy if diagnosis uncertain.
- DDx : Tinea corporis, vitiligo, psoriasis.

Pityriasis Versicolor (Tianea Versicolor)


Pityriasis Versicolor (Tianea Versicolor)

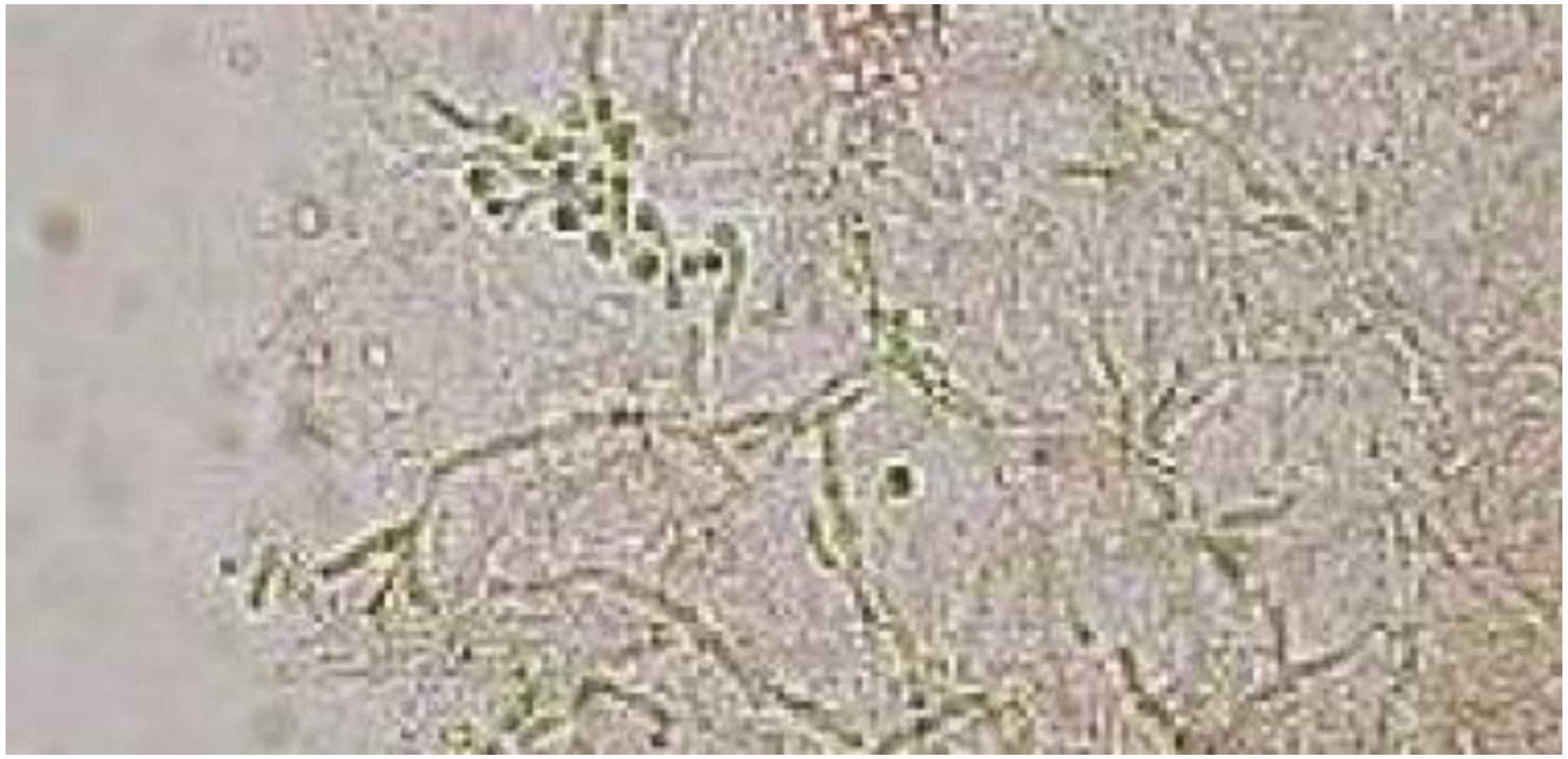

Pityriasis Versicolor (Tianea Versicolor)

- Management
  - Topical or systemic treatment.
  - Nizoral shampoo (ketoconazole 2%) applied onto dampened trunk skin, lathered for 5 min before rinsing, x 3 d.
  - Topical selenium sulfide 2.5% shampoo applied for 15 min x 3 d.
  - Topical nizoral cream 2% (ketoconazole) bid x 2 wk.
  - Systemic ketoconazole 200 mg po qd x 5 – 7 d or fluconazole 400 mg x 1. Postinflammatory hypopigmentation may persist for 6 – 12 mo.
  - Even with treatment, tendency to recur in summer.
  - Zinc pyrithione soap lather may be applied to the body 1 – 3 times weekly for prevention.

Tinea (Dermatophyte) Infection

- Dermatophyte digest and invade keratin then infect skin, nails and hair; incubation period = 1-3 weeks
- *Trychophyton, Microsporum, Epidermophyton* species commonly involved.
- Risk Factors; Hot, humid environment, sweating or maceration of the skin, occlusive footwear, Diabetes mellitus, immunosuppression
- History: Asymptomatic; occasionally mild pruritus

Tinea (Dermatophyte) Infection

- Physical; Scalp hair and general body surfaces mostly affected during childhood; hand, foot or nail infections are more common after puberty
- Immunologic response to a dermatophyte infection may result in a dermatophytid reaction: Vesicular eruption on acral surfaces, especially the palms

Tinea (Dermatophyte) Infection

Tinea (Dermatophyte) Infection

Tinea (Dermatophyte) Infection

- Investigations; Skin scraping analysis with KOH prep – Septate hyphae branching at various angles are seen; fungal culture
- DDx; Eczema, granuloma annulare, psoriasis

Tinea Capitis

- Caused by invasion of stratum corneum and hair shaft with fungal hyphae.
- Four clinical infection patterns;
  - Seborrheic dermatitis type- Diffuse, patchy scale on scalp
  - Black dot pattern- hyphae invade hair shaft. Hair then broke at scalp surface. Broken shaft like black dots. Round area of alopecia without inflammation
  - Inflammation tinea capitis (kerion)- Deep boggy round masses with pustules, surface exudate
  - Pustular- Pustules areas without scaling, significant hair loss may be present, look like scalp bacterial infection.

Seborrheic dermatitis type – Tinea Capitis

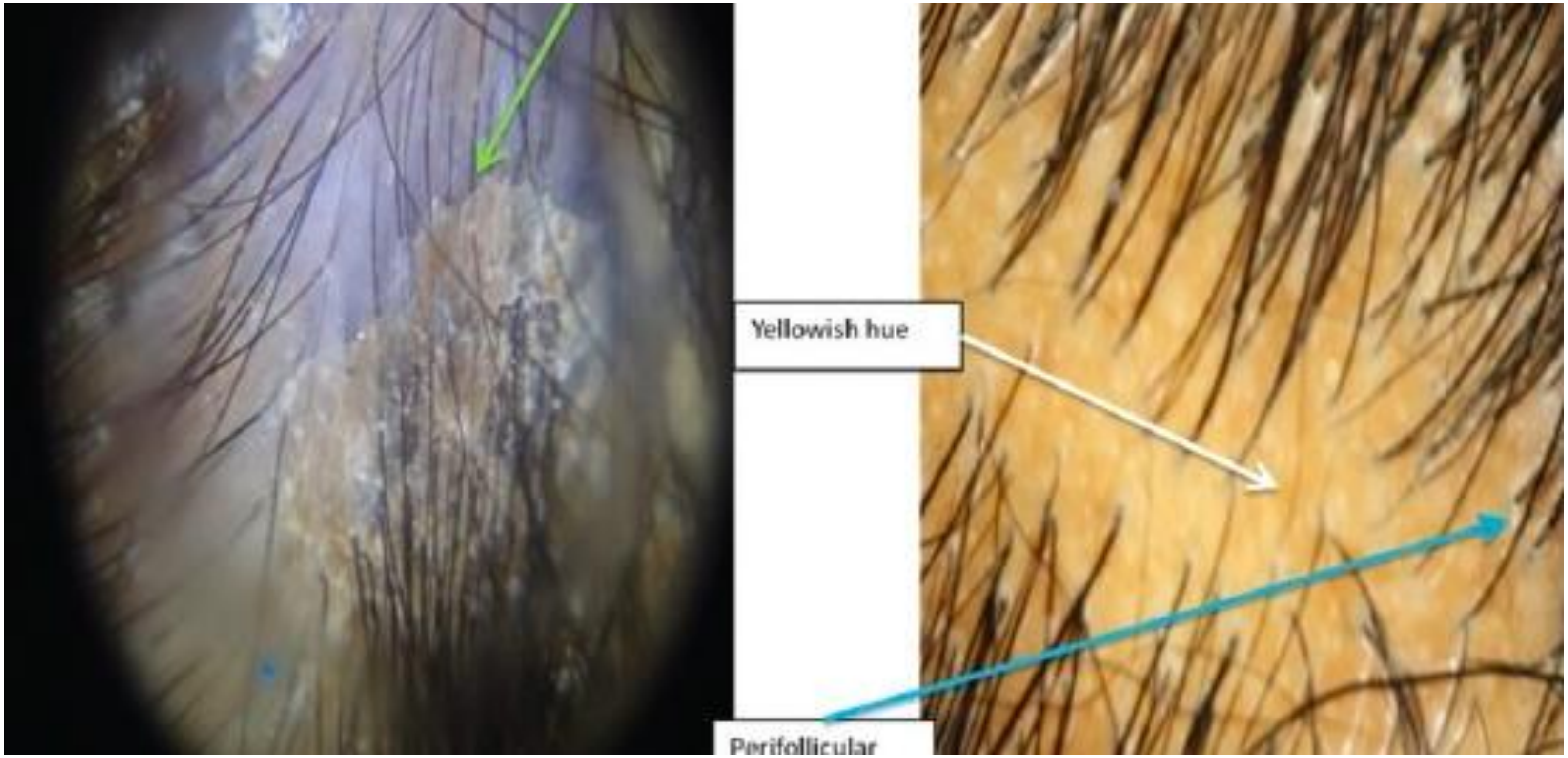

Black dot pattern – Tinea Capitis

Inflammation tinea capitis (kerion) – Tinea Capitis

Tinea Capitis

- Management

- Examine sibling and household members, clean or discard contaminated objects.
- Griseofulvin; usually 6-12 weeks
- Itraconazole and fluconazole; taken for 4-8 weeks. A single dose of 150 mg once weekly for 4 weeks also be effective for older children
- Shampoo with selenium sulfide 1% or ketoconazole every other day for the first 2 weeks, then twice weekly throughout course of rest of oral therapy. Shampoo is left for 5 min
- Consider suppression kerion inflammation with prednisolone 1-2 mg/kg qd or intralesional triamcinolone 10 mg/cc

Erythema Nodosum

- Common form of septal panniculitis that is usually a reactive skin response to an associated trigger

- Infections; Bacterial (e.g., streptococcal pharyngitis), microbacterial (tuberculosis)
- Drugs; e.g., oral contraceptives, sulfonamides
- Sarcoidosis
- Inflammatory bowel disease
- Behcet disease
- Malignancy
- - Pregnency

Erythema Nodosum

- History; Lesions may be associated with fever, malaise, leg edema and arthralgia. Resolution after 2-6 wk
- Physical; painful, dull, erythematous nodules 1-5 cm in diameter, located on anterior lower legs of young woman. No ulceration, discharge or scarring
- Investigation; Through review of systems: CBC, UA, chest x-ray and throat swab
- DDx; Insect bite reaction, erysipelas, urticaria

Erythema Nodosum

Erythema Nodosum

- Management

- Investigate for and treat underlying cause.
- Most patients benefit from bed rest, applying ice or cool compresses, elevating legs & NSAIDs
- Less common Tx choice; Oral prednisolone, colchicine, dapsone

Necrobiosis lipodica

- An inflammatory condition of degenerative collagen. When present, it is often associated with diabetes
- Lesions usually develop slowly and are often asymptomatic, onset may occur at any age but the disease most common starts at 3^{rd} – 4^{th} decade. About 75% of those affected are women

Necrobiosis lipodica

- Physical Findings
  - Lesion are usually limited to the anterior shins but may be seen on calve and thighs, and rarely on the arms, hands, feet and scalp.
  - They begin as round, violaceous patches and slowly expand. The advancing border is red, and the central area turns a characteristic orange-yellow brown. The central area atrophies and shows a shiny, waxy surface with prominent telangiectasias.
  - Ulceration may occur, particulary after trauma, in about 15% of cases. These ulcers are exquisitely tender.
  - The number or severity of lesions or ulcerations has not been correlated with the degree of diabetic control.
  - The course is unpredictable. Lesions usually heal with atrophic scarring, or can be chronic and recurrent.

Necrobiosis lipodica

- Treatment
  - Topical and intralesional steroids slow the inflammation but may promote further atrophy. Middle- to high-potency corticosteroids can be used under occlusion.
  - Intralesional injections of triamcinolone acetonide 10 mg/mL canbe helpful.
  - A short course (5-6 weeks) of oral corticosteroids can be considered if disease activity and symptoms are seversе, but this is rarely the case.
  - Pentoxifylline (Trental) 400mg t.i.d. has been advocated by some and has been used in combination with low-dose aspirin for ulcerating necrobiosis lipoidica.
  - Skin grafting can be performed for extensive disease.

Seborrheic Keratosis - SK

- Common idiopathic benign epidermal growth
- Common in fourth decade
- Males and females equally affected
- More common in fair skin
- Possibly autosomal dominant
- Gradual development; occasionally pruritic or sore

Seborrheic Keratosis - SK

- Well circumscribed epidermal growth, raised lesions
- Waxy round-oval papules and plaques with verrucous or crusted surface. Sharp border
- “Stuck on” appearance
- Starts as light brown macule larger and verrucous with time
- Also, smooth-surfaced lesions contain dark or light round horn pearls embedded in the lesion or protruding from the surface.
- Variably pigmented and size
- Most commonly: trunk, neck, arms, scalp; wide range of size

Seborrheic Keratosis - SK

- *Leser-Trelat sign:* Sudden, eruptive seborrheic keratoses in elderly individuals, often with inflammatory base may be a sign of an associated internal (stomach cancer & others) malignancy as part of paraneoplastic syndrome

Leser Trelat Sign

Courtney N. Bernett; George J. Schmieder.

Author Information

Last Update: March 21, 2019.

Introduction

Go to:

The sign of Leser-Trelat is considered to be a fairly rare paraneoplastic cutaneous marker of internal malignancy with the hallmark finding being an abrupt eruption of multiple seborrheic keratoses. [1][2][3][4]To date, there have been no standardized or quantified diagnostic criteria defining the sign of Leser-Trelat, but instead, the colloquial definition includes an increase in the number and/or size of the seborrheic keratoses. Seborrheic keratoses (SK) are a nearly

Seborrheic Keratosis - SK

- Investigation: Clinical diagnosis; skin biopsy if uncertain.
- DDx: AK, BCC, lentigo, melanoma, nevus, skin tag, wart

Seborrheic Keratosis - SK

Seborrheic Keratosis - SK

- Treatment may be indicated for symptomatic lesions which are inflamed, irritated or bleeding.
- THERAPIES
  - Cryotherapy; for flat to minimally raised lesions.
  - Light cautery/electrodessication
  - Shave excision
  - Laser
    - Not effective for thicker lesions
    - Ruby (694nm)
    - Alexandrite (755nm)
    - CO_2
    - Erbium

Actinic Keratosis - AK

- Most common precancerous lesions in humans, and more prevalent in fair-skinned individuals who tan poorly and burn easily.

- Found in sun-exposed skin
  - Face, ears
  - Neck, forearms
  - Dorsal hands
- Outdoor occupations, ionizing radiation and arsenic exposure

Actinic Keratosis - AK

- Common in skin type I-III
- Secondary to cumulative keratinocyte damage
- Atypical keratinocytes confined to epidermal basal layer
- < 1% progress to skin cancer (squamous cell carcinoma, SCC)

Actinic Keratosis - AK

- Clinical appearance

  - Slightly erythematous, rough, scaly papules on sun-exposed areas

  - May be difficult to see, but often feel rough: Palpation is essential to diagnosis.

  - Most commonly in the elderly

  - DDx: BCC, Bowen disease, SCC

  - Investigation: Biopsy if recurrent, unresponsive to treatment, or pronounced hyperkeratosis and induration

Actinic Keratosis - AK

- Treatment options
  - Topical
    - 5% 5-flourouracil (Carac, Efudex) applied bid for 2-4 wk
    - 5% Imiquimod (Aldara) applied three to five times weekly for 12 wk
    - Expect erythema, irritated, inflamed and crusting; follow-up visit in 1-2 wk to evaluate severity of side effects

Actinic Keratosis - AK

- Liquid Nitrogen Cryotherapy for limited lesions
- Electrodesication and curettage, CO_2 laser
- Dermabrasion
- Chemical peel (for numerous AKs)
  - Serial medium depth TCA
- Light Therapy
  - PDT with ALA. Pulsed CO_2

Sun-awareness and protection advice

Basal Cell Carcinoma - BCC

- Most common cutaneous malignancy derived from stem cells of epidermis. Locally invasive, slow-growing, rarely metastasizes (unless patients is immunocompromised)
- Etiology: Chronic UV exposure (Cumulative sun exposure is primary risk factor), radiation, immunosuppression, genetics (e.g., nevoid basal cell carcinoma syndrome)
- History: Persistent, nonhealing papule or nodule that ulcerates or bleeds (beefy-red smooth erosive nodule). Common in elderly (most common after 40) Caucasians.

Basal Cell Carcinoma - BCC

- Physical: Pearly papule or nodule with telangiectases, rolled border; central crust or ulceration.
- Distributed mostly on sun-exposed areas, i.e., head and neck (85%). Variants: Superficial, nodular, sclerosing (morpheaform), pigmented
- DDx: Melanoma, nevus, SCC
- Investigations: Biopsy must be performed to confirm diagnosis and classify subtype.

Basal Cell Carcinoma - BCC

- Physical Findings

- Nodular BCC: Most common variant. A pearly white, almost translucent, dome-shaped papule with overlying telangiectasias. Papule or nodule enlarges slowly, may become flattened in center or may develop a raised, rolled, translucent border. Frequently ulcerates, bleeds, becomes crusted in center

Basal Cell Carcinoma - BCC

- Pigmented BCC: contains melanin, may therefore resemble melanoma
- Superficial BCC: least aggressive form. More commonly on trunk, extremities. Circumscribed, round to oval, red, scaling plaque resembles eczema, psoriasis, extramammary Paget disease or Bowen disease
- Sclerosing BCC : Most subtle and least common variant. Smooth, pale white to yellow papules. Resembles scar tissue. Borders may be difficult to discern. Higher rate of recurrence

Basal Cell Carcinoma - BCC

Nodular BCC

Basal Cell Carcinoma - BCC

Pigmented BCC

Basal Cell Carcinoma - BCC

Superficial BCC

Basal Cell Carcinoma - BCC

Sclerosing BCC

Basal Cell Carcinoma - BCC

- Management

- Advise that metastases and death are extremely rare. Vast majority cause no major problem, but should be treated

- Without treatment, BCCs persist, enlarge, ulcerate, invade, destroy surrounding structures

- Tx options depend on histological subtype and location: Liquid nitrogen cryotherapy (requires experience), curettage & electrodessication (most common Tx), excision, Mohs micrographic surgery, imiquimod cream for superficial subtype, 5-FU, CO_2 laser, radiation therapy

- Advise on sun protection

Basal Cell Carcinoma - BCC

- Electrosurgery of obvious tumor. The 5 year cure rate approach 92%
- Primary excision is preferred for non-facial, well-defined nodular. The 5 year rate approach 90%
- Mohs microsurgery is a highly specialized, tissue-sparing method of excision used for difficult tumors with contiguous growth. It is also used for recurrent BCC, histological aggressive forms of BCC, such as sclerotic BCCs, and tumors in anatomically important locations such as around eyes, nasal alar, mouth and ears.

Basal Cell Carcinoma - BCC

- Radiation therapy may be useful for difficult-to-treat tumors, such as eyelids, and for patients unable to tolerate surgery. The 5 year cure rates are roughly 90%
- Photodynamic therapy is an evolving chemotherapeutic modality for superficial BCC
- Topical imiquimod 5% cream is an immune response modifier shown to be about 85% effective or better for superficial BCC. It is less effective for nodular BCC

Squamous Cell Carcinoma (SCC)

2nd most common form of skin cancer (after BCC) arising in sun exposed areas in elderly; due to malignant keratinocytes with metastatic potential.

- Etiology : Chronic UV-damage is the primary cause, immunosuppression, burns leg ulcers, chemical carcinogens (e.g., tar), HPV; can occur in discoid lupus, lichen sclerosus, & any scarring processes.
- History : Slow-growing, nonhealing scaly papule on sun-exposed area of head, neck, dorsal hands, and forearms; also affects mucous membranes (lower lip: M >> F, smokers, 10% - 15% metastatic rare); rare in dark skin.

Squamous Cell Carcinoma (SCC)

- Physical : Firm indurated papule, plaque, or nodule with adherent rough scale on sun-exposed areas. Normally with necrotic crusted center. Removal of crust reveals central cavity filled with necrotic keratin debris.
- Actinic keratosis is considered a precursor lesion; actinic cheilitis is the precursor on lip.
- Ultimately, tumors metastasize, via the lymphatics to other organs
- Investigations : Biopsy (to mid-dermis) for confirmation.
- DDx : AK, BCC, SK, amelanotic melanoma, wart.

Squamous Cell Carcinoma (SCC)

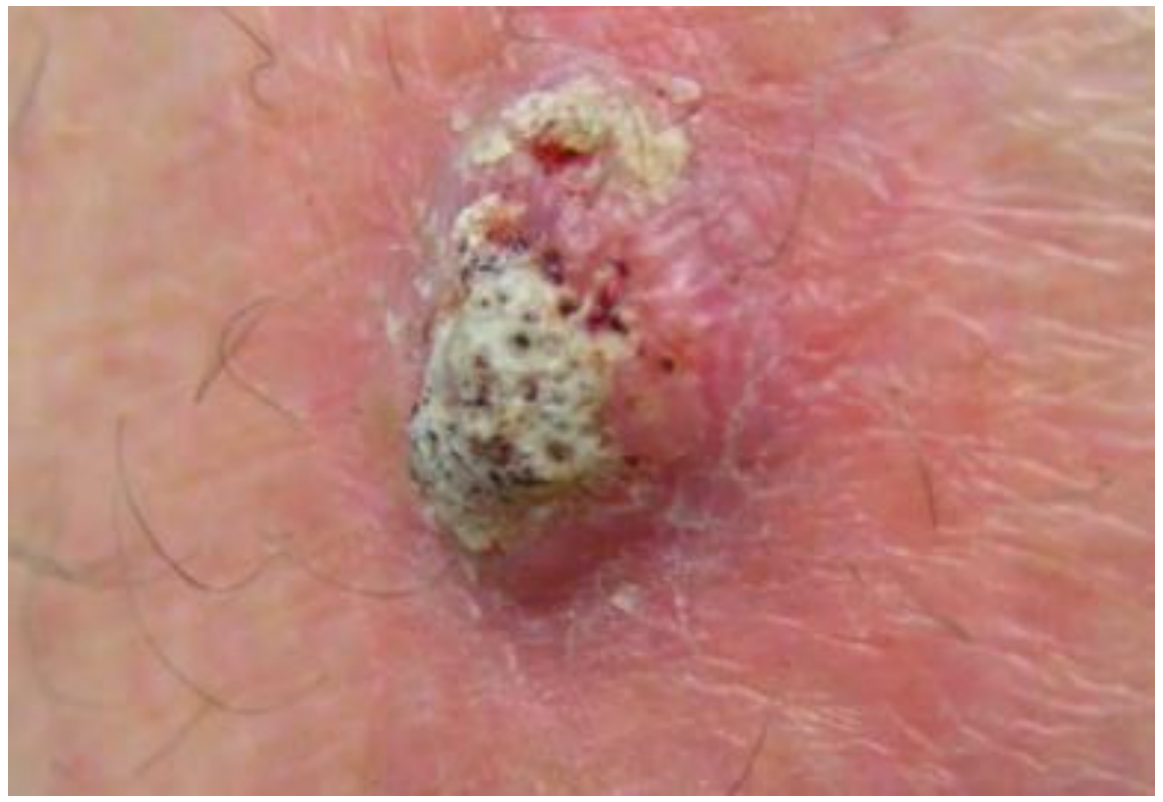

Squamous Cell Carcinoma (SCC)

- Management
  - Wide local excision with histologic confirmation of margins.
  - Lymp node biopsy indicated for suspected nodal disease
  - Liquid nitrogen cryotherapy
  - Mohs micrographic surgery
  - Less commonly topical imiquimod or radiation
  - Advide on sun protection.

Melanoma

- Etiology : Melanocyte-derived skin cancer. May arise within a previously existing nevus or dysplastic nevus, but ~ 70% arise *de novo*
- History : Risk factors
  - Fair complexion: Red/blonde hair, blue/green eyes, tendency to freckle and burn.
  - Sun exposure, particularly blistering sunburns during childhood.
  - Personal of family history of melanoma; Genes involved in some cases: CDKN2A, BRAF.
  - Giant congenital melanocytic nevi or multiple dysplastic nevi.

Melanoma

- Physical: Pigmented macule or plaque with some or all of the following features

ABCDE of melanoma:

- Asymmetry
- Borders (irregular)
- Color variegation
- Diameter (> 6mm)
- Evolution (lesion change by history)

Melanoma

Classically divided into subtypes based on clinical and histopathologic features:

1. Superficial spreading malignant melanoma – 60%-70% of melanomas.
2. Nodular melanoma.
3. Acral-lentiginous melanoma – Most common form in blacks, Asians, and Hispanics, mostly on volar skin of the palms or soles and the nailbeds.
4. Lentigo maligna melanoma – Develops from a lentigo maligna, usually on the face of elderly, slow-growing.
5. Amelanotic melanoma – Pink-red.
6. Rare variants.

Superficial spreading malignant melanoma

Nodular melanoma

Acral-lentiginous melanoma

Lentigo maligna melanoma

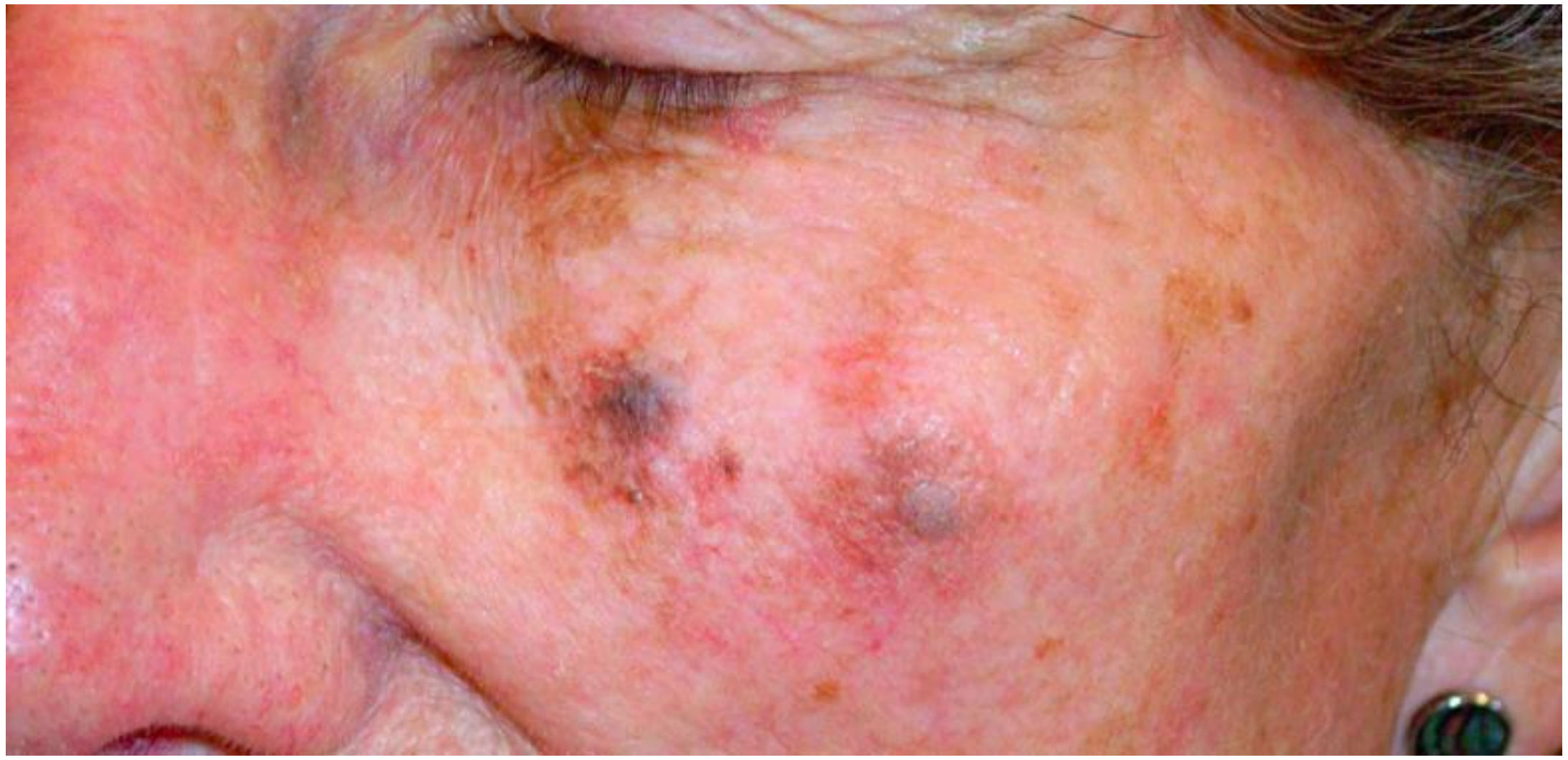

Amelanotic melanoma

Melanoma

- Most common sites of local and/or regional metastases- Draining lymph node basins and the skin between the primary site and the lymph nodes.

- Most common sites of systemic metastases – Lung, Liver, brain (#1 cause of death), bone, and gastrointestinal tract.

- Investigations: Dermoscopy (ABCD rule), excisional biopsy if melanomais suspected

- Most important prognostic indicator is maximal thickness of tumor invasion on biopsy (Breslow depth in mm)

- DDx: BCC, blue or dysplastic nevus, SK

Melanoma

- Management

- Wide surgical excision; based on Breslow depth: 5 mm for melanoma in situ, 1 cm for melanoma <1mm, 2 cm for melanoma >1mm
- Sentinel lymph node biopsy depending on clinical
- Adjuvant high-dose interferon & IL-2 may provide benefit for metastatic disease
- Perfusion chemotherapy for extremity melanoma
- Radiation

Atopic Dermatitis

- Chronic inflammatory dermatosis affecting 10%-20% of children (esp. infants and young children)
- Etiology: Cutaneous immune dysfunction; IgE-mediated; genetics. Strong associated with personal and family history of atopy (eczema, asthma)
- History: “Pruritus” is a hallmark (“the itch that rashes”). Aggravating factors: sweating, contact sensitivity, secondary infection, wool, food allergy, stress/anxiety.

Atopic Dermatitis

- Acute: Erythematous, excoriated, scaling patches and plaques; more lichenification in chronic forms.
- Distribution:

  - Infants: Cheeks, forehead, scalp, extensor surfaces of extremities

  - Child: Flexural surfaces- antecubital and popliteal fossae, wrists, ankles

  - Adults: Hands, flexural. The prominent finding is lichenification; this indicates a long – standing problem.

- Lesions can be secondarily infected with staphylococcal organisms: impetigo

Atopic Dermatitis

Infants: Cheeks, forehead, scalp, extensor surfaces of extremities

Atopic Dermatitis

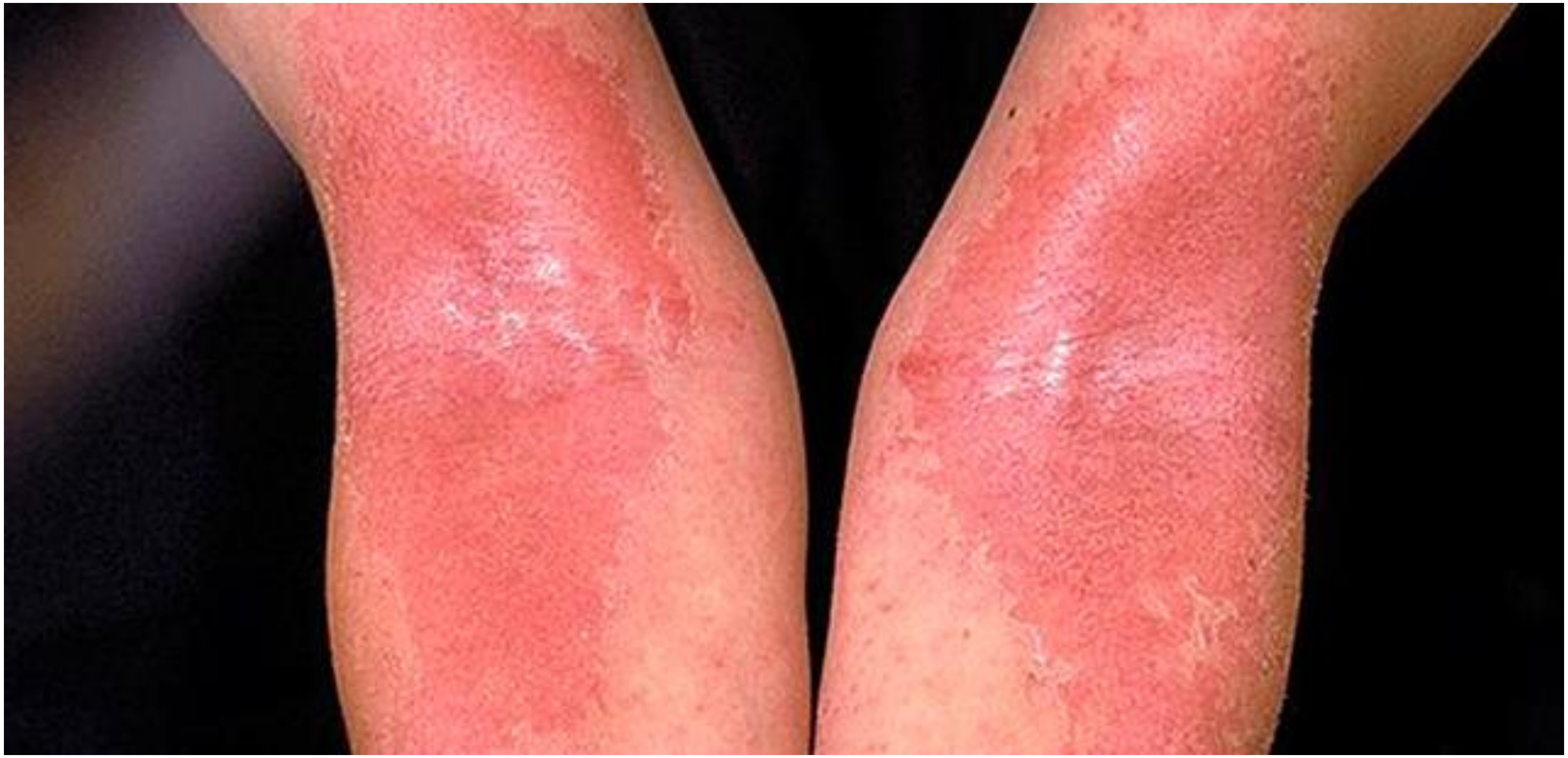

Child: Flexural surfaces- antecubital and popliteal fossae, wrists, ankles

Atopic Dermatitis

Adults: Hands, flexural. The prominent finding is lichenification ; this indicates a long – standing problem

Atopic Dermatitis

- DDx: Contact dermatitis, psoriasis, seborrheic dermatitis
- Investigation: Allergy or RAST testing of little value (Patch test if dermatitis pattern changes or refractory to treatment.
- Diagnosis Requires: History of an itchy skin condition (or parental report of scratching/rubbing by the child)

Atopic Dermatitis

- **Plus ≥3 of :**

1. History of involvement of skin crease (antecubital, popliteal, anterior ankles or around the neck) or cheeks in children < 10 years

2. Personal history of asthma or hay fever (or history of atopic disease in 1st degree relative if < 4 years of age)

3. History of generalized dry skin in the past year.

4. Visible flexural dermatitis (or eczema on the cheeks/forehead and outer limbs in children < age 4 years)

5. Onset under the age of 2 (do not use as criterion if patient is < age 4 years)

Atopic Dermatitis

- Minor, less specific feature:

- xerosis, ichthyosis, palmar hyperlinearity, keratosis pilaris. Immediate type 1 skin test responses, dermatitis of hands and feet, cheilitis, nipple eczema, increased susceptibility to cutaneous infection, perifollicular accentuation

Atopic Dermatitis

- Management

 - Elimination of precipitating irritants: avoid wool and synthetic fabrics; wear cotton clothes, humidifier at home; dietary restriction if specific verified food allergy; stress reduction.

- Skin hydration: Baths with emollients, apply thick nonfragranced emollient immediately after bath.
- Topical steroids: 1% hydrocortisone ointment bid to face and folds, midpotency steroids bid to other effected areas; ointments more occlusive and more effective than creams.

- Management

  - Steroid-sparing topical immunomodulators can be used bid in children > 2 yr: Pimecrolimus cream – mild to moderate eczema. Tacrolimus – moderate to severe eczema.

  - Oral antihistamines with sedative effect may offer symptomatic relief of the associated pruritus, e.g., hydroxyzine (3-5 mg/kg/d divided tid/qid)

  - If secondarily infected: antibiotic therapy

  - If patients refractory to conventional therapy, other systemic Tx choices include: PUVA or UVB light therapy, systemic steroids (short courses), methotrexate, cyclosporine: usually administered by dermatologist